



a healthier world through
sonographer expertise

Ultrasound guided peripheral intravenous catheter (PIVC) insertion

Disclaimer: This guideline is intended for use by qualified sonographers who have obtained the appropriate certifications and are authorised under relevant state or territory legislation to perform ultrasound-guided peripheral intravenous catheter insertions. It aims to support safe, effective, and consistent practice by outlining procedural standards, training requirements, and clinical considerations. The guideline is designed to improve first-attempt success rates, reduce complications, and enhance patient outcomes – particularly for individuals with difficult intravenous access. It is the responsibility of each practitioner to ensure they are operating within their individual scope of practice and in accordance with local laws, institutional policies, and professional regulatory requirements. This guideline does not confer the right to perform PIVC insertions without appropriate training, credentialing, and legal authorisation.

Level 2, 93–95 Queen Street
Melbourne 3000 VICTORIA

T +61 3 9552 0000
F +61 3 9558 1399

www.sonographers.org.au

Date: September 2025

Contents

Background	03
Glossary	04
Sonographer competency, training and ongoing assessment	05
Best practices for peripheral intravenous catheter insertion	06
Indications for ultrasound-guided peripheral intravenous catheter insertion	06
Contraindications for peripheral intravenous catheter insertion	06
Potential complications and management	06
Insertion considerations	07
Artefacts and pitfalls	08
Ensuring safe reprocessing of ultrasound transducers	09
Conclusion	09
References	10
Appendix 1: <i>Template ultrasound-guided peripheral intravenous catheter assessment</i>	11
Appendix 2: <i>Ultrasound-guided peripheral intravenous catheter insertion best practices and steps</i>	12
Appendix 3: <i>Central Government, States, and Territories drug and poison regulation</i>	19
Appendix 4: <i>Acknowledgements</i>	19

Peripheral venous access is a fundamental component of healthcare.^{1–4} A peripheral intravenous catheter (PIVC), commonly referred to as an IV, cannula, or drip, is a small flexible catheter that is inserted through the skin into a peripheral vein in the arm or hand.^{1,5–7} PIVCs are used to deliver fluids, medicines and intravenous contrast dye, playing an important role in the diagnosis, treatment, and resuscitation of patients.^{1,2,5,7–13}

Over a billion PIVC insertions are performed worldwide each year, making it one of the most common healthcare procedures.¹⁴ They are the most used invasive medical device in healthcare, with up to 70% of hospitalised patients requiring at least one PIVC during their stay.^{2,3,5,10–12,15} Traditionally PIVC insertion has been performed using landmark-driven palpation, known as blind insertion, where vessel selection and insertion are guided by anatomical landmarks, including the inspection and palpation of veins.¹² Blind PIVC practice is usually restricted to two attempts by one individual with subsequent attempts made by a more experienced colleague.^{6,8,15,16} The first-attempt success rate for PIVC insertion varies widely, ranging from 40% to 67%, depending on the skill of the clinician and patient-specific factors.^{3,10,17} When a PIVC fails, the likelihood of subsequent PIVC failure increases.⁵ Unsuccessful attempts lead to delayed medical treatments, multiple puncture sites, increased progression to central venous access and patient discomfort.^{3,10,17} This discomfort can result in needle-phobia and hospital avoidance.²

Several patient factors, such as poor vessel palpability, limited vessel visibility, smaller vein size, obesity, history of intravenous drug use, diabetes mellitus, previous chemotherapy, dehydration, hypovolaemia, burns, and vessel mobility can make PIVC insertion challenging.^{1,4,10,13,17–19} To increase success rates, health professionals may employ additional techniques, including the use of anaesthetics, heat packs, sedation, distraction, tourniquets, transillumination devices, and ultrasound guidance.¹⁰

Approximately 30% of adults and up to 65% of children have difficult intravenous access (DIVA), typically defined as two or more failed insertion attempts.^{17,19} DIVA is characterised by veins that are not visible or palpable, often requiring technological aids for successful vascular access.^{3,4,17,19} Clinical guidelines and escalation pathways are recommended to identify DIVA patients, maximising first-time insertion success, and prevention of PIVC insertion failure by advocating for ultrasound-guided PIVC (USGPIVC).^{3,17}

USGPIVC insertion has significantly improved success rates, particularly for patients with DIVA. First used in 1991, USGPIVC has become a standard approach worldwide for patients with DIVA, showing success rates of 90% compared to traditional blind techniques.^{3,10,12,20,21}

This technique reduces needle insertion attempts, complication rates, and redirections (partial withdrawal with advancement in a new direction), while increasing successful PIVC placements, resulting in improved patient satisfaction, better long-term health preservation, and reduced need for central line placement.^{3,8,9,17,19,21,22}

Sonographer led PIVC can relieve the workload pressure on radiologists, allowing them to focus on other more complex tasks such as interventional procedures, thereby contributing to improved workflow in radiology departments.^{10,23} Sonographers, with their established expertise in using ultrasound technology, are uniquely equipped to perform USGPIVC insertions, particularly for patients with DIVA.⁸ Patients may benefit from reduction in waiting times and improved care.²³ This guideline aims to provide sonographers with comprehensive instructions and best practices for performing USGPIVC insertions, ensuring high success rates in first-attempts, combined with improved patient health outcomes, with the ongoing management of the PIVC to be provided by the treating physician and healthcare team.

Glossary

Aseptic non-touch technique (ANTT)	A clinical practice that prevents contamination during invasive procedures by ensuring key parts and key sites are not touched, reducing the risk of introducing microorganisms from hands, surfaces, or equipment. ^{24,25}
PIVC competent clinician	A healthcare professional who is trained, competent, and authorised to perform PIVC insertion.
Competency	Refers to the ability to perform a specific task or job effectively and efficiently. For PIVC insertion, achieving a satisfactory standard of competency requires completing a relevant formal certification, with current supervised clinical practice or simulation based education, or a combination of both, and having current experience and expertise in PIVC insertion. ²⁴
Difficult intravenous access (DIVA)	Used to describe veins that are not easily visible or palpable, often requiring advanced techniques for successful cannulation. ^{3,4,17,19}
Extravasation	The leakage of intravenous fluids into surrounding tissues which can cause tissue damage and requires immediate attention and intervention. ²⁶
Haematoma	A localised collection of blood outside the blood vessel, typically resulting from vessel injury. In the context of PIVC, it may occur following unsuccessful or traumatic insertion attempts.
High-level disinfection (HLD)	A process to eliminate microorganisms to ensure safety of ultrasound transducers.
Key parts	Key parts of the procedural equipment that can contact the patient's blood. Key parts, if contaminated, have the potential to cause infection. ²⁶ Examples include the syringe tip and injection needle itself.
Key sites	Key sites are the intended insertion site and any portal of entry into the patient, for example open wounds, cannulation site, and injection site. ²⁶
Peripheral	Refers to a vein that is more distal/ further away from the heart or the centre of a particular body part (i.e at upper or lower extremities).
Peripheral intravenous catheter (PIVC)	A small, sterile flexible tube inserted into a peripheral vein to deliver fluids, medications or contrast media. Also known as an IV, cannula or drip. ^{12,57-13}
Standard precautions	The minimum work practices that sonographers must use at all times for all patients to minimise the risk of transmitting infection. ²⁴
Sterile field	An area free of microorganisms, maintained during procedures to prevent infection.
Ultrasound guided peripheral intravenous catheter (USGPIVC)	A technique that utilises ultrasound imaging to guide the insertion of a peripheral intravenous catheter into the target blood vessel. ^{3,8,9,17,19,21,22}

Sonographer competency, training and ongoing assessment

To ensure safe and effective USGPVVC insertion, sonographers must meet defined competency standards through structured training and continuous evaluation.

Ensuring clinical competency

Insertion of a PIVC is an invasive procedure that should only be performed by sonographers who are suitably trained, working within their scope of practice, and are well-equipped to handle the nuances of PIVC insertion to minimise the risk of infection.^{6,16,24,25,27–29} Sonographers should adhere to the Australian Commission on Safety and Quality in Health Care (ACSQHC)⁵ and the New Zealand Te Tāhū Hauora Health Quality and Safety Commission.³⁰ They must understand the importance of ensuring that PIVCs are inserted and maintained by clinicians who have undergone rigorous training and competency assessments.⁵ It is important that clinicians are proficient in current evidence-based practices that focus on preserving vessel health and preventing complications.⁵

The ACSQHC specially mandates that any clinician who is in the process of achieving competency in PIVC insertion must be supervised by a clinician who has already been trained and assessed as competent.⁵ This supervision ensures that the trainee can develop their skills under the guidance of an experienced professional, thereby maintaining high standards of patient care and safety.⁵ This structured approach to training and supervision helps to minimise the risk of complications and enhances the overall quality of care provided to patients requiring PIVCs.⁵

Training requirements

Sonographers must have completed both didactic instruction and a practical assessment of competence. Training should encompass anatomy, physiology, experience with blind cannulation techniques to ensure proficiency, knowledge of aseptic techniques to

prevent infection, and an understanding of potential complications such as bleeding and inadvertent arterial puncture.^{8,20,26}

Each healthcare provider must define how sonographers meet competency requirements and audit outcomes.^{10,15,31} Competency should be assessed based on specific criteria, including the ability to identify suitable veins, maintain a sterile field, and successfully insert the catheter with minimal patient discomfort. Sonographers should receive certification upon successful completion of training and competency assessment. It is recommended that sonographers observe a minimum of five USGPVVC placements performed by a competent clinician, followed by at least five successful supervised insertions to demonstrate proficiency. Successful insertion is indicated by immediate blood flashback, unobstructed saline flush without resistance, or absence of pain, swelling, or signs of extravasation during or after flushing.^{7, 18, 26, 28} See [Appendix 1 USGPVVC assessment template](#).

Ongoing competency assessment

Ongoing competency assessments are important to ensure sonographers maintain proficiency in the latest techniques and best practices.¹⁰ Sonographers should participate in annual refresher training that covers new developments and reinforces core skills. Sonographers should be a part of a system for continuous performance monitoring, which includes regular audits and feedback sessions to identify areas for improvement.

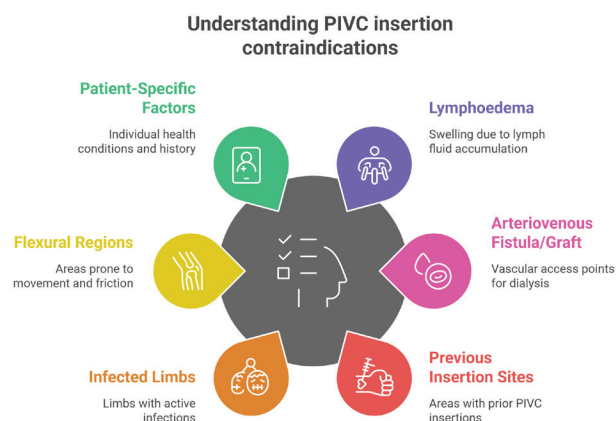
Indications for USGPIVC insertion

Clinical Scenario	Description / Examples
DIVA	History of DIVA, non-palpable or non-visible veins; ≥2 failed cannulation attempts.
Patient-specific factors	Obesity, IV drug use, diabetes, chemotherapy, dehydration, burns, scarred tissue, mobile/fragile veins. ^{1,10,13,17}
Failed traditional insertion	Landmark-based techniques unsuccessful or likely to fail.
Urgent access needs	Emergency or high-acuity settings requiring timely vascular access.
Avoiding central access	Peripheral access feasible with ultrasound, avoiding escalation to central lines.

Contraindications for PIVC insertion

Ensuring that PIVC insertion sites are free from contraindications is fundamental for minimising patient discomfort and preventing adverse outcomes.¹⁶ The following conditions should be considered contraindications for PIVC insertion:

Figure 1: Contraindications of PIVC insertion



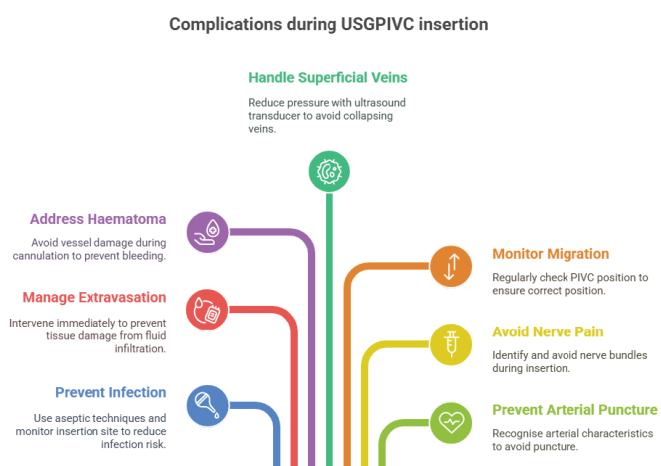
- **Flexural regions:** Avoid inserting PIVCs in areas of flexion, such as the antecubital fossa or wrist, as these sites are prone to mechanical complications and discomfort due to joint movement.^{5,15,24}
- **Infected limbs:** Do not insert a PIVC in an infected limb, such as one affected by cellulitis, due to the heightened risk of introducing or exacerbating an infection.²⁴

- **Previous insertion sites:** Refrain from using areas where previous PIVC insertions have occurred, as these sites may have residual bruising, phlebitis, or scarring, which can interfere with successful insertion and increase the risk of infection.¹⁶
- **Lymphoedema:** Do not insert a PIVC in a limb affected by lymphoedema, as this condition can lead to increased swelling, discomfort, and may hinder successful placement.^{5,7,15,24}
- **Arteriovenous fistula or graft:** Avoid limbs with an arteriovenous fistula or graft, commonly used for dialysis, to prevent damage to these critical access points.^{5,7,15,24}

Potential complications and management

PIVC insertion, while a common and generally safe procedure, is not without risks. Understanding and managing potential complications is important to ensure patient safety and improve outcomes. Common complications associated with PIVC insertion include but are not limited to:

Figure 2: Potential complications



- **Infection and phlebitis:** PIVCs provide direct access to the bloodstream, increasing the risk of infection during insertion or while in-situ.²⁴ Hospital-acquired complication (HAC) related to PIVC infections are associated with increased morbidity and mortality, prolonged hospital stays, and higher healthcare costs, and are considered preventable adverse events.^{5,15,24} Phlebitis, or inflammation of the vein, occurs in up to 54% cases and often necessitates PIVC replacement.^{2,32} This condition can lead to significant patient discomfort, extended hospital stays, increased healthcare costs, and patient death.^{2,32}

Prevention strategies:

- Use the smallest appropriate gauge in consideration of the total fluid volume to be applied and the potential duration of the intended infusion.
- Maintain aseptic technique.
- Monitor the insertion site for early signs of infection.

Extravasation Refers to the extravascular infiltration of intravenous fluids into the surrounding tissue, which can cause swelling, pain, and potential tissue damage.²⁶ This complication can occur if the PIVC dislodges from the vein or if the vein ruptures. Adequate immediate intervention is required to prevent severe tissue damage.

Haematoma: Unsuccessful cannulation attempts can damage the vessel, causing haemorrhage into the surrounding tissue.³³ This can result in swelling, bruising, discomfort, and reduces the imaging quality and needle visualisation for USGPIVC.

Superficial veins: Insertion challenges include dealing with very superficial veins, such as those on the dorsum of the hand, which are easily compressible and difficult to visualise and follow during insertion.^{18,26} These veins are prone to collapse under the pressure of the ultrasound transducer or the PIVC, making successful insertion more challenging.^{18,26}

Migration: PIVCs may migrate out of the vein after insertion due to factors such as patient movement, or skin laxity, or vein elasticity.^{18,26} Close monitoring of the PIVC's position is essential prior to use, dressing and securement practices will reduce the risk of dislodgement or complications.

Nerve injury: Nerve pain may occur if a peripheral nerve is inadvertently contacted during insertion, resulting in sharp or radiating pain, tingling, or numbness.³⁴ To minimise risk, sonographers should identify and avoid nerve bundles and cease insertion immediately if the patient reports sudden pain or paraesthesia.³⁴

Arterial puncture: An inadvertent complication that may occur during PIVC insertion, particularly when veins and arteries lie in close proximity, such as in the antecubital fossa or near the brachial artery.¹⁴ Clinically, arterial puncture may present as bright red, pulsatile blood return, or rapid blood flow into the catheter. Sonographers must recognise that arteries are non-compressible, have thicker, more echogenic walls, and show pulsatile flow on Doppler.²⁰ If arterial puncture is suspected, the PIVC should be withdrawn immediately, and firm pressure be applied to the insertion site.

Insertion considerations

Effective USGPIVC insertion relies on a structured approach that prioritises patient safety, procedural accuracy, and infection control. For a full step-by-step procedural guide, including patient preparation, equipment setup, insertion technique, and postprocedure care, refer to [Appendix 2: USGPIVC Insertion Best Practices and Steps](#).

Sonographers should always:

- Select the appropriate insertion approach (transverse or longitudinal) based on vein depth, visibility, and personal proficiency.^{8,10,26} See [Determining the best approach: Transverse or longitudinal](#).
- Evaluate the optimal insertion site by considering vein characteristics, patient comfort, and anatomical landmarks.^{7,15,20,24,26,35} See [Evaluating optimal insertion site and vein assessment](#).
- Choose the smallest suitable PIVC gauge and appropriate length to ensure stability and reduce complications.^{7,24,28,36} Ensure the PIVC diameter does not exceed one-third of the vein's diameter and select a vein that is long enough to accommodate the PIVC length while leaving sufficient space for surrounding blood flow. For superficial veins accessed via palpation, PIVCs typically range from 20 to 30mm in length. In contrast, USGPIVC often target deeper veins, which require longer PIVCs, typically between 40 to 50mm, to ensure secure placement and reduce the risk of dislodgement or infiltration. See [Table 1 Size and gauge of PIVC](#) and [Determining the appropriate PIVC size and gauge](#).
- Prepare the skin using recommended antiseptic solutions and maintain aseptic technique throughout the procedure. See [Steps for effective skin preparation before PIVC insertion](#).
- Apply pain management strategies, including topical or injectable anaesthetics, as appropriate and in accordance with local regulations.^{17,37–40} See [Pain management strategies for USGPIVC insertion](#).
- Prepare equipment aseptically, insert the PIVC using ultrasound guidance while maintaining sterile technique, secure and flush the line. See [PIVC insertion steps](#).
- Provide aftercare and document the procedure. See [Post insertion care and documentation](#).

Table 1: Size and gauge of PIVC

Each sonographer should consult the product guide for the specific type of PIVC stocked at their workplace, as the flow rate can vary for PIVCs of the same gauge from different vendors.^{7,41,42}

Colour	Gauge	External diameter	Common uses
Orange	14	2.1mm	Trauma, rapid blood transfusion, surgery
Grey	16	1.8mm	Rapid fluid replacement, trauma
Green	18	1.3mm	Trauma / rapid fluid administration
Pink	20	1.1mm	General medication, fluid administration
Blue	22	0.9mm	General medication
Yellow	24	0.7mm	Difficult access, paediatric patients
Purple	26	0.6mm	Difficult access, paediatric patients

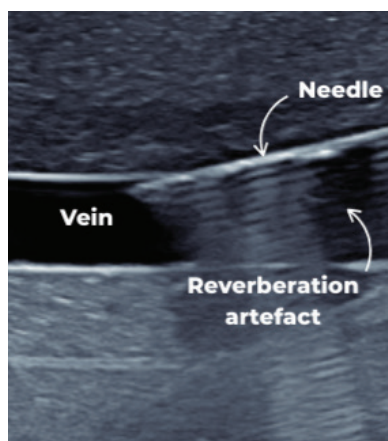
Artefacts and pitfalls

When performing USGPVVC insertion, sonographers must be aware of common artefacts and pitfalls that can affect the accuracy and success of the procedure.²⁶ Understanding these challenges and how to address them is crucial for achieving optimal outcomes.

REVERBERATION ARTEFACTS

- **Description:** Reverberation artefacts occur when the ultrasound beam bounces between two strong reflectors, such as the needle and the skin surface, creating multiple, equally spaced echoes.^{26,35,43} This can make it difficult to distinguish the true position of the needle tip.^{26,35}
- **Mitigation:** To reduce reverberation artefacts, use higher frequency transducers, adjust the angle of the ultrasound transducer and the needle, or try a transverse approach to view the vascular anatomy during the insertion process.

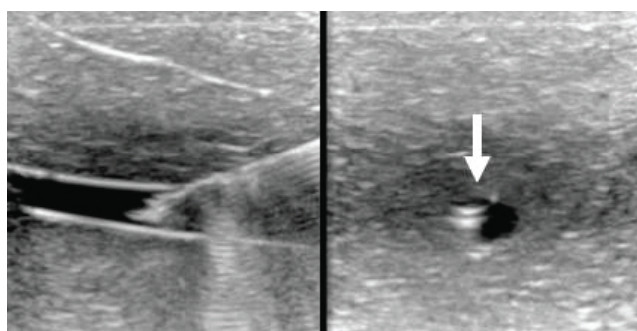
Figure 3: Reverberation artefact



SLICE THICKNESS ARTEFACTS

- **Description:** Slice thickness artefacts occur when the ultrasound beam width includes structures outside the intended imaging plane, leading to the appearance of structures that are not actually in the plane.^{35,44} For example, this can make the needle appear to be in the vein when it is actually in the vessel wall.^{19,35}
- **Mitigation:** To minimise slice thickness artefacts, use a high-frequency linear transducer, ensure the field of view is as narrow as possible, align the needle with the ultrasound beam, and check in a second imaging plane.⁴⁴

Figure 4: Slice thickness artefact

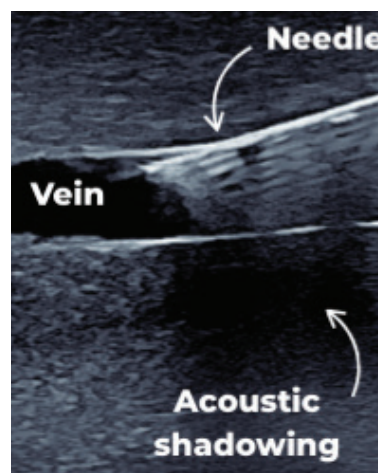


35

ACOUSTIC SHADOWING

- **Description:** Acoustic shadowing occurs when a structure, such as a PIVC, bone or vascular calcification, blocks the ultrasound beam, creating a shadow behind it.⁴³ This can obscure the view of the underlying structures, making it difficult to visualise the vein and needle.⁴³
- **Mitigation:** Adjust the position of the ultrasound transducer to obtain a different angle.

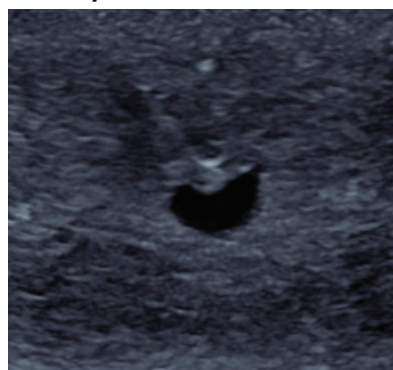Figure 5: Acoustic shadowing



NEEDLE TIP VISUALISATION

- **Description:** Difficulty in visualising the needle tip can lead to inaccurate placement and increased risk of complications.⁴³ This is particularly challenging in the transverse (out-of-plane) approach, where the needle body can be misinterpreted as the needle tip.⁴³
- **Mitigation:** Use the longitudinal (in-plane) approach to visualise the entire length of the needle. If using the transverse approach, employ techniques such as slight needle movements or a small volume (<2ml) sterile saline injection to enhance needle tip visibility. For further information on longitudinal and transverse approach see [Determining the best approach: Transverse or longitudinal](#). Utilise beam steering or needle profiling software set up, if available. Ensure that the ultrasound monitor, patient, and patient's peripheral access point are aligned within the sonographer's line of sight.

Figure 6: Needle tip visualisation



VEIN COMPRESSION

- **Description:** Excessive pressure from the ultrasound transducer can compress the vein, making it difficult to visualise and access the target vein.²⁰ This is especially problematic with superficial veins.
- **Mitigation:** Apply minimal pressure with the ultrasound transducer to avoid compressing the vein.²⁰ Use a gel pad, a stand-off pad, or a tourniquet to improve visualisation of superficial veins without applying excessive pressure.

PATIENT MOVEMENT

- **Description:** Patient movement during the procedure can lead to loss of needle and vein visualisation, increasing the risk of complications.

- **Mitigation:** Ensure the patient is comfortable and well-positioned before starting the procedure. Support the arm securely using the ultrasound examination bed or an arm board, if required. Provide clear instructions to the patient to remain still.

By being aware of these common artefacts and pitfalls and employing strategies to mitigate them, sonographers can improve the accuracy and success rates of USGPVC insertions, leading to better patient outcomes.

Ensuring safe reprocessing of ultrasound transducers

Proper cleaning of ultrasound transducers before and after PIVC insertion is crucial to prevent contamination and ensure patient safety. The following guidelines are recommended:

- **Use of transducer covers:** Use an aseptic transducer cover during PIVC procedures to minimise the risk of contamination.^{45,46}
- **Cleaning process:** Clean the transducer thoroughly before and after the procedure to remove any visible soil or residue. Pay special attention to grooves and crevices.^{45,47} Use appropriate cleaning agents and follow the manufacturer's instructions for cleaning and disinfection.⁴⁶
- **Classification and risk:** Ultrasound transducers must be disinfected according to their classification based on the level of patient contact:
 - **Low-level disinfection (LLD)** is appropriate for non-critical transducer, which are those that come into contact only with intact skin and do not contact blood, non-intact skin, or mucous membranes. LLD is sufficient in these cases to reduce the risk of cross-contamination.
 - **High-level disinfection (HLD)** is required for semi-critical transducers, which are those that come into contact with non-intact skin, blood,

mucous membranes, or are likely to contact body fluids. These transducers pose a higher risk of potential contamination and must undergo HLD, regardless of whether a transducer cover was used.⁴⁵ This can be achieved using a high-level TGA-approved chemical or thermal sterilant, or medical device disinfectant. Ensure that the disinfectant is compatible with the transducer prior to HLD.⁴⁵ Maintain detailed records of the HLD process, including the date, time, and method of disinfection.^{45,47} Ensure compliance with standards for reprocessing reusable medical devices (RMDs) and other devices in health and non-health related facilities.^{45,47} Implement a system of patient traceability to enable recall procedures in case of decontamination failure.^{45,47}

The level of disinfection required is determined by the intended use of the ultrasound transducer. When a transducer is designated for use in a semicritical application, HLD should be performed prior to the procedure. By adhering to these guidelines, sonographers can ensure the safe and effective reprocessing of ultrasound transducers, thereby reducing the risk of infection and maintaining high standards of patient care.

Conclusion

USGPVC insertion allows vascular access for patients, particularly those with DIVA. By leveraging ultrasound technology, sonographers can achieve higher success rates, reduce complications, and enhance patient comfort and satisfaction. Adhering to the best practice principles ensure sonographers are well-equipped to perform USGPVC insertions

safely and effectively, improving patient outcomes and preserving vessel health. Continuous training, competency assessments, and adherence to infection control standards are important for maintaining high standards of care.

References

1. Amick A, Feinsmith S, Davis E, Sell J, MacDonald V, Trinquero P, et al. Simulation-based master learning improves ultrasound-guided peripheral intravenous catheter insertion skills of practicing nurses. *Simul. Healthc.* 2022;17(1):7–14. Available from: <https://doi.org/10.1097/SIH.0000000000000545>
2. Evison H, Carrington M, Keijzers G, Marsh NM, Sweeny AL, Byrnes J, et al. Peripheral intravenous cannulation decision-making in emergency settings: A qualitative descriptive study. *BMJ Open.* 2022;12(3). Available from: <https://doi.org/10.1136/bmjopen-2021-054927>
3. Schults J, Marsh N, Ullman A, Kleidon T, Ware R, Byrnes J, et al. Improving difficult peripheral intravenous access requires thought, training and technology (DART3): A steppedwedge, cluster randomised controlled trial protocol. *BMC Health Serv Res.* 2023;23(1):587. Available from: <https://doi.org/10.1186/s12913-023-09499-0>
4. Jørgensen R, Laursen C, Konge L, Pietersen PI. Education in the placement of ultrasoundguided peripheral venous catheters: A systematic review. *Scand. J. Trauma. Resusc. Emerg. Med.* 2021;29(1):83. Available from: <https://doi.org/10.1186/s13049-021-00897-z>
5. Australian Commission on Safety and Quality in Health Care. Management of peripheral intravenous catheters clinical care standard. 2021. Available from: <https://www.safetyandquality.gov.au/standards/clinical-care-standards/management-peripheralintravenous-catheters-clinical-care-standard>
6. University Hospitals Bristol and Weston NHS Foundation Trust. Peripheral venous cannulation policy and procedure (adults & children). 2023. Available from: https://www.uhbw.nhs.uk/assets/1/24-638_peripheral_venous_cannulae_policy_and_procedure_aug_23_redacted.pdf
7. Queensland Ambulance Service. Clinical practice procedures: access / peripheral intravenous catheter insertion. 2024. Available from: https://www.ambulance.qld.gov.au/_data/assets/pdf_file/0021/219162/CP-Peripheral-IV-Access.pdf
8. Gilmore C, Burnett R, Straw R, Kroll W, Franklin I. Ultrasound guided intravenous cannula insertion — reflection. *J. Med. Radiat. Sci.* 2021;59(3):73–6. Available from: <https://doi.org/10.1002/jr.2051-3909.2012.tb00178.x>
9. Primdahl S, Weile J, Clemmesen L, Madsen K, Subhi Y, Petersen P, et al. Validation of the peripheral ultrasound-guided vascular access rating scale. *Med.* 2018;97(2):9576. Available from: <https://doi.org/10.1097/MD.00000000000009576>
10. Hoskins M, Nolan B, Evans K, Phillips B. Educating health professionals in ultrasound guided peripheral intravenous cannulation: a systematic review of teaching methods, competence assessment, and patient outcomes. *Med.* 2023;102:33624. Available from: <https://doi.org/10.1097/MD.00000000000033624>
11. Bridey C, Thilly N, Lefevre T, Maire-Richard A, Morel M, Levy B, et al. Ultrasound-guided versus landmark approach for peripheral intravenous access by critical care nurses: A randomised controlled study. *BMJ Open.* 2018;8(6):020220. Available from: <https://doi.org/10.1136/bmjopen-2017-020220>
12. Pham M, Aldous R, Brincat S. Implementation of ultrasound-guided cannulation training for foundation doctors. *Clin. Med. (Lond.)*. 2024;24(6):100256. Available from: <https://doi.org/10.1016/j.clinme.2024.100256>
13. Erickson C, Liao M, Haukoos J, Douglass E, DiGeronimo M, Christensen E, et al. Ultrasound-guided small vessel cannulation: Long-axis approach is equivalent to short-axis in novice sonographers experienced with landmark-based cannulation. *West. J. Emerg. Med.* 2014;15(7):824–30. Available from: <https://doi.org/10.5811/westjem.2014.9.22404>
14. National Center for Biotechnology Information (US). StatPearls: peripheral line placement. StatPearls Publishing. 2023. Available from: <https://www.ncbi.nlm.nih.gov/books/NBK539795/>
15. South Eastern Sydney Local Health District, NSW Government. Peripheral intravenous cannulation (PIVC) insertion, care and removal (adults). 2024. Available from: <https://www.seslhd.health.nsw.gov.au/node/9255>
16. Canberra Health Services, ACT Government. Peripheral intravenous cannula (PIVC) and midline catheters—the insertion and management of adults and children. 2022. Available from: https://www.canberrahealthservices.act.gov.au/_data/assets/word_doc/0009/1981575/Peripheral-Intravenous-Cannula-PIVC-and-Midline-Catheters-the-Insertion-and-Management-of-Adults-and-Children-Not.DOC
17. Paterson R, Schults J, Slaughter E, Cooke M, Ullman A, Kleidon T, et al. Review article: peripheral intravenous catheter insertion in adult patients with difficult intravenous access: a systematic review of assessment instruments, clinical practice guidelines and escalation pathways. *Emerg. Med. Austral.* 2022; 34:862–70. Available from: <https://doi.org/10.1111/17426723.14069>
18. Gottlieb M, Sundaram T, Holladay D, Nakitende D. Ultrasound-guided peripheral intravenous line placement: A narrative review of evidence-based best practices. *West. J. Emerg. Med.* 2017;18(6):1047–54. Available from: <https://doi.org/10.5811/westjem.2017.7.34610>
19. Blanco P. Ultrasound-guided peripheral venous cannulation in critically ill patients: a practical guideline. *Ultrasound J.* 2019;11(1):27. Available from: <https://doi.org/10.1186/s13089019-0144-5>
20. National Center for Biotechnology Information (US). StatPearls: ultrasound intravascular access. Stat Pearls Publishing. 2024. Available from: <https://www.ncbi.nlm.nih.gov/books/NBK448093/>
21. Mitchell E, Jones P, Snelling PJ. Ultrasound for pediatric peripheral intravenous catheter insertion: A systematic review. *Pediatrics.* 2022;149(5):2021055523. Available from: <https://doi.org/10.1542/peds.2021-055523>
22. Carr P, Rippey J, Cooke M, Higgins N, Trevenen M, Foale A, et al. Derivation of a clinical decision-making aid to improve the insertion of clinically indicated peripheral intravenous catheters and promote vessel health preservation. An observational study. *PLoS One.* 2019;14(3):0213923. Available from: <https://doi.org/10.1371/journal.pone.0213923>
23. Bwanga O, Kayembe R, Sichone J. Intravenous cannulation and administration of contrast media by radiographers: A literature review to guide the training and practice in Zambia. *Afr Health Sci.* 2022;22(2):629–37. Available from: <https://doi.org/10.4314/ahs.v22i2.72>
24. Government of Western Australia, Department of Health. Insertion and management of peripheral intravenous cannulae in healthcare facilities. 2023. Available from: <https://www.health.wa.gov.au/About-us/Policy-frameworks/Public-Health/Mandatory-requirements/Communicable-Disease-Control/Infection-Prevention-and-Control/Insertion-and-Management-of-Peripheral-Intravenous-Cannulae>
25. York Teaching Hospital, NSH Foundation Trust. Peripherally inserted vascular cannula (PIVC) guidelines (Version 1). 2016. Available from: <https://www.yorkhospitals.nhs.uk/secmsfile/?id=863>
26. Clinical skills development service. Ultrasound guided peripheral intravenous cannulation (Course ID: 434). 2025. Available from: <https://central.csd.sld.edu.au/central/courses/434>
27. Toh V, Reed W, Robinson J. An investigation into the perceptions of radiographers in the Greater Sydney metropolitan area on performing intravenous contrast media administration. *Radiographer.* 2007;54(3):9–15. Available from: <https://doi.org/10.1002/jr.2051-3909.2007.tb00070.x>
28. Department of Health, Queensland Government. Peripheral intravenous catheter (PIVC) Guideline. 2015. Available from: https://www.health.qld.gov.au/_data/assets/pdf_file/0030/444756/icare-pivc-pointofcare-maintain.pdf
29. Zingg W, Barton A, Bitmead J, Eggimann P, Pujol M, Simon A, et al. Best practice in the use of peripheral venous catheters: A scoping review and expert consensus. *Infection Prevention in Practice.* 2023;5(2). Available from: <https://doi.org/10.1016/j.infpip.2023.100271>
30. New Zealand Te Tāhū Hauora Health Quality and Safety Commission. Peripheral intravenous catheter infections. 2024. Available from: <https://www.hqsc.govt.nz/our-work/infection-prevention-and-control/our-work/peripheral-intravenous-catheter-infections/>
31. Primdahl S, Todsén T, Clemmesen L, Knudsen L, Weile J. Rating scale for the assessment of competence in ultrasound-guided peripheral vascular access – a delphi consensus study. *J. Vasc. Access.* 2016 Sep 1;17(5):440–5. Available from: <https://doi.org/10.5301/jva.5000581>
32. Takahashi T, Nakagami C, Murayama R, Abe-Doi M, Matsumoto M, Sanada H. Automatic vein measurement by ultrasonography to prevent peripheral intravenous catheter failure for clinical practice using artificial intelligence: development and evaluation study of an automatic detection method based on deep learning. *BMJ Open.* 2022;12(5):051466. Available from: <https://doi.org/10.1136/bmjopen-2021-051466>
33. Miliani K, Taravella R, Thillard D, Chauvin V, Martin E, Edouard S, et al. Peripheral venous catheter-related adverse events: evaluation from a multicentre epidemiological study in France (the CATHEVAL Project). *PLoS One.* 2017;12(1):0168637. Available from: <https://doi.org/10.1371/journal.pone.0168637>
34. Culverwell E. Canterbury district health board intravenous cannulation resource book. 2021. Available from: <https://edu.cdhb.health.nz/Hospitals-Services/Health-Professionals/Education-and-Development/Study-Days-and-Workshops/Documents/CDHB%20PIVC%20Resource%20Book%20%202021.pdf>
35. Australasian Sonographers Association. ASA OLM Advance: Ultrasound guided IV cannulation. 2022. Available from: <https://www.sonographers.org/cpds/asa-advance---US-guided-IV-Cannulation>
36. WA Country Health Service, Government of Western Australia. Peripheral intravenous cannula (PIVC) guideline. 2022. Available from: <https://www.wacountry.health.wa.gov.au/-/media/WACHS/Documents/About-us/Policies/Peripheral-Intravenous-Cannula-PIVCGuideline.pdf?thn=0>
37. Balyanyuk I, Ledonne G, Provenzano M, Bianco R, Meroni C, Ferri P, et al. Distraction technique for pain reduction in peripheral venous catheterization: randomized, controlled trial. *Acta Biomed.* 2018;89(4-S):55–63. Available from: <https://doi.org/10.23750/abm.v89i4-S.7115>
38. Sharp R, Muncaster M, Baring CL, Manos J, Kleidon TM, Ullman AJ. The parent, child and young person experience of difficult venous access and recommendations for clinical practice: a qualitative descriptive study. *J Clin Nurs.* 2023;32(17–18):6690–705. Available from: <https://doi.org/10.1111/jocn.16759>
39. Bond M, Crathorne L, Peters J, Coelho H, Haasova M, Cooper C, et al. First do no harm: pain relief for the peripheral venous cannulation of adults, a systematic review and network meta-analysis. *BMC Anesthesiol.* 2016;16(81). Available from: <https://doi.org/10.1186/s12871-0160252-8>
40. Royal Children's Hospital Melbourne. Intravenous access – peripheral. 2019. Available from: https://www.rch.org.au/clinicalguide/guideline_index/intravenous_access_peripheral/
41. Pedagogy Continuing Nurse Education. Peripheral IV catheter chart. (n.d.). Available from: <https://pedagogyeducation.com/Resources/Infusion/Peripheral-IV-Catheter-Chart>
42. Denex international. A comprehensive guide: IV cannula sizes, colors, flow rates and usage. 2023. Available from: <https://www.ivcannula.com/blog/iv-cannula-sizes-colors-flowrates-and-usage>
43. Reusz G, Sarkany P, Gal J, Csomos A. Needle-related ultrasound artifacts and their importance in anaesthetic practice. *Br J Anaesth.* 2014;112(5):794–802.
44. Nakayama Y, Takeshita J, Nakajima Y, Shime N. Ultrasound-guided peripheral vascular catheterization in pediatric patients: A narrative review. *Crit Care.* 2020;24(1):592. Available from: <https://doi.org/10.1093/bja/aet585>
45. Australasian Society for Ultrasound in Medicine (ASUM). Guidelines for reprocessing ultrasound transducers. *Australas J Ultrasound Med.* 2017. 23;20(1):30–40. Available from: <https://doi.org/10.1002/ajum.12042>
46. Australasian Sonographers Association (ASA). ASA clinical statement. Infection prevention and control. 2021, May. Available from: <https://www.sonographers.org/publicassets/09d59b70-d0de-ef11-9137-00050568796d8/Infection-Prevention-and-ControlGuidelines-for-Sonographers.pdf>
47. Australian Commission on Safety and Quality in Health Care. Australian guidelines for the prevention and control of infection in healthcare. 2024. Available from: <https://www.safetyandquality.gov.au/publications-and-resources/resource-library/australian-guidelinesprevention-and-control-infection-healthcare>
48. Queensland Government. Peripheral intravenous catheter: insertion. 2019. Available from: https://www.health.qld.gov.au/_data/assets/pdf_file/0025/444751/icare-pivc-pointofcareinsertion.pdf
49. Australian Commission on Safety and Quality in Health Care. 5 moments for hand hygiene. 2009. Available from: <https://www.safetyandquality.gov.au/our-work/infectionprevention-and-control/national-hand-hygiene-initiative/what-hand-hygiene/5-momentshand-hygiene>
50. Evans N, Ratchford E. Catheter-related venous thrombosis. *Vasc. Med.* 2018;23(4):411–3. Available from: <https://doi.org/10.1177/1358863X18779695>
51. Metro North Hospital and Health Service, Queensland Health. Standing order for administration. 2024.
52. Tanaka K, Judo K, Ambe K, Kawai H, Yamazaki S. A histological study of vasoconstriction by local anesthetics in mandible. *Anesth Prog.* 2018; 65(4):244–8. Available from: <https://doi.org/10.2344/anpr-65-03-15>

Appendices

Appendix 1: Template USGPIVC assessment

Assessment criteria	Yes	No
Preparation for the patient		
Explanation, consent, reassurance, education		
Physical comfort and privacy		
Check for contraindications (e.g., axillary clearance, cellulitis)		
Select an appropriate vein under ultrasound guidance		
Clean gel off transducer		
Preparation of equipment		
Gather required equipment, prepares equipment, ensure transducer is clean or disinfected to the required level and perform hand hygiene		
Select correct PIVC size and gauge		
Procedure		
Don protective equipment (if required)		
Prepare equipment using aseptic technique		
Release tourniquet		
Apply tourniquet		
Perform hand hygiene		
Clean insertion site with application of an appropriate topical antiseptic using circular scrubbing motion, moving away from the insertion site.		
Allow to dry		
Apply sterile gel to transducer		
Attend to patient comfort		
Perform hand hygiene. Don gloves		
Apply aseptic cover on the transducer		
Select vessel		
Pierce skin at 35-45° angle above entry site		
Check for PIVC position using ultrasound		
Once position confirmed, ensure needle tip is central in the vessel and advances PIVC forward		
Attach needleless connector (bung) to catheter or extension set		
Release tourniquet, remove needle, safely dispose in sharps bin		
Applies transparent semipermeable membrane (TSM) dressing		
Perform hand hygiene		
Attend to patient comfort		
Documentation of the procedure in the patient's record, noting insertion time (PIVCs should be removed when clinically indicated)		
Reprocessing of transducer and cleaning of ultrasound machine		
Comments / feedback:		

Appendix 2: USGPIVC insertion best practices and steps



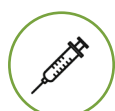Check indications and patient assessment

- Consider the clinical indications for PIVC and the expected duration of use. Select a site that will accommodate the necessary therapy and minimise the risk of complications over time.^{7,16,24,48}
- Assess the patient, explain the procedure, and obtain informed consent.^{6,7,25,28}
- Confirm any allergies, particularly to antiseptics or local anaesthetics.⁶



Hand hygiene

- Perform hand hygiene before and after patient contact and before donning and after removing gloves.⁴⁶
- Use an alcohol-based hand rub or wash hands with soap and water if visibly soiled.^{5,15,24,28,46,49}
- When using soap and water, rub hands together for a minimum of 20 seconds, paying particular attention to the tips of fingers, thumbs and the areas between the fingers.⁴⁶



Preparation of equipment

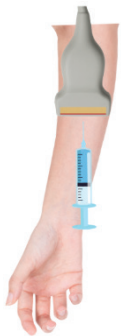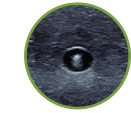
- Gather all necessary equipment, check for sterility and expiry dates, and clean the trolley with alcohol/ detergent wipes.^{28,31}
- Set up the aseptic area immediately before the procedure to minimise contamination risk.²⁸
- Position the patient comfortably in an examination chair or on a bed.²⁸
- Ensure privacy and adjust the bed level as needed.²⁸
- Position the ultrasound machine on the contralateral side for direct line of sight.¹⁸
- Ensure proper working posture, stabilise the transducer and needle, and position the apparatus relative to the puncture site.³¹
- Select a high-frequency linear transducer (10-15MHz) for optimal visualisation of superficial structures.^{26,35}
- Adjust the ultrasound settings (preset, gain, depth, focus) for the best image quality.^{26,31}





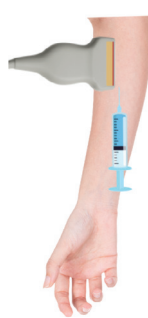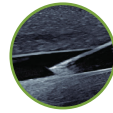
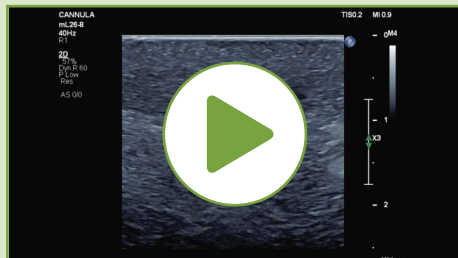
Determining the best approach: Transverse or longitudinal

- Choose between the longitudinal (in-plane) and transverse (out-of-plane) approaches. ^{8,10,26}
- Each approach has its advantages and considerations, and the choice depends on the specific clinical scenario and sonographer preference.



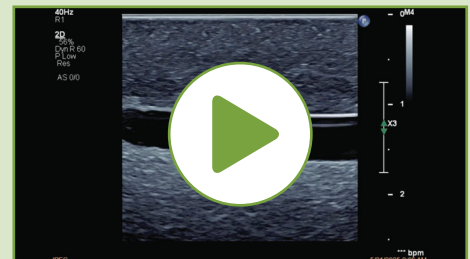Transverse (out-of-plane) approach

- Provides a cross-sectional view of the vein, allowing for easy identification of the vessel and surrounding structures. ^{10,20,21,26,44} This can be particularly useful in identifying the vein's location relative to other anatomical features.
- Only the needle tip is visible on the ultrasound screen, which can make it more challenging to track the progress of the needle and ensure it remains within the vein. ^{19,26,35} Must be adept at recognising the needle tip to avoid complications.
- As the needle tip advances, the ultrasound transducer should be moved simultaneously to continuously visualise and track the needle tip.
- Generally easier to learn and perform, making it a good option for sonographers who are new to USGPIVC insertion. ^{19,35}



Longitudinal (in-plane) approach

- The entire length of the needle is visible on the ultrasound monitor. This provides precise control and continuous visualisation during insertion, reducing the risk of inadvertent puncture of the posterior wall of the vein. ^{10,18,19,44}
- The needle is aligned with the ultrasound beam, making it easier to track its progress and adjust the angle as needed. ^{20,26}
- The longitudinal approach requires more practice to master, as maintaining the needle within the plane of the ultrasound beam can be challenging. ³⁵
- Requires a steady hand and a good understanding of ultrasound imaging to use this approach effectively. ³⁵



Choosing the optimal approach

- Consider patient-specific factors such as vein depth, size, and location. The longitudinal approach may provide better visualisation and control for deeper veins. This compares to the transverse approach which may be more straightforward for superficial veins.
- Choose the approach that aligns best with comfort and proficiency. ³⁵ Both approaches require practice and skill to perform effectively.
- The urgency of the procedure and the patient's condition may influence the choice of approach. In emergency situations, the approach that allows for the quickest and most reliable insertion should be selected.





Evaluating optimal insertion site

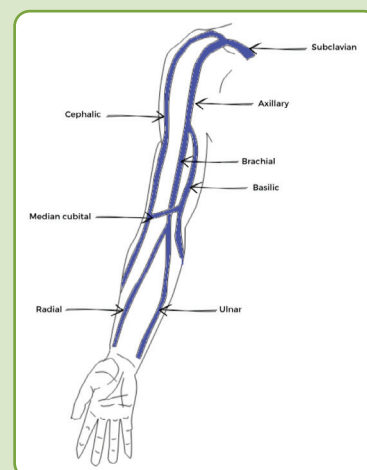
Evaluating the insertion site is an important step in ensuring the success of PIVC insertion and minimising complications.

- **Ask the patient if they have a preference for the PIVC location:** Whenever possible, involve the patient in the decision-making process to enhance comfort and cooperation.⁵ Ask the patient where previous successful PIVC attempts have been made.
- **Prioritise veins in the non-dominant arm:** This can enhance patient comfort and reduce interference with daily activities.^{5,15,24}
- **Prioritise inserting PIVCs in the most peripheral veins in the upper limb:** Avoid areas of flexion, such as the antecubital fossa or wrist, as these sites are prone to mechanical complications and discomfort due to joint movement.^{7,15,24} The preferred area for insertion is in the lower forearm.
- **Consider the surrounding anatomy, including nerves and arteries:** Nerves will appear as hyperechoic bundles containing multiple small hypoechoic nerve fibres. Veins are easily compressible when pressure is applied with an ultrasound transducer, whereas arteries generally do not collapse and have a thicker, more hyperechoic walls with pulsatile movement.²⁰ Use colour and pulsed wave Doppler to assist in differentiating.²⁰
- **Assess the potential risk of infection at the insertion site:** Ensure the site is free from signs of infection, such as redness, swelling, or warmth.^{5,15,24} Clean the skin with soap and water before applying antiseptic solution, if necessary.

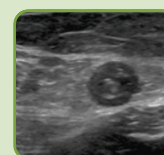


Vein assessment

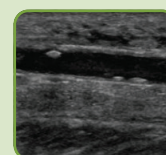
- **Consider environmental factors such as room or outdoor temperature:** Cold environments can cause vasoconstriction, resulting in smaller vein diameters. Heat packs may be useful.
- **Consider patients with significant hypovolaemia:** These patients are likely to have very low venous pressure, resulting in few visible peripheral veins even with a tourniquet applied.²⁶
- **Avoid veins in the lower limb:** These veins should not be routinely used due to the increased risk of embolism and thrombophlebitis.^{25,28,50}
- **Perform an ultrasound assessment of both upper extremities:** Identify the ideal location, vessel size, distinguish between arteries and veins, and vessel path prior to commencing the cannulation procedure.^{18,3,7,26,31}
 - Veins greater than 0.4 cm in diameter have been shown to have a higher success rate for cannulation.^{18,19}
 - Veins located at a moderate depth (0.3-1.5cm from the skin surface) are easier to cannulate compared to vessels that are closer to the skin surface (less than 0.3cm) or deeper (greater than 1.5cm).^{18,19}
 - Ideal veins are superficial, anechoic, thin-walled, compressible, and contain minimal branching and no appreciable valves.^{19,26,35}
- **Select target vessel:**
 - The cephalic vein is an excellent target vessel for USGPIVC due to its superficial position and large calibre.^{18,26}
 - The basilic vein is also a good option for PIVC; however, sonographers should be aware that peripherally inserted central catheters (PICC) are also commonly inserted into the basilic vein.^{18,26}
 - The brachial vein carries to the risk of inadvertent arterial injury/cannulation and is best to be avoided unless absolutely necessary.²⁶
 - The median cubital vein is another useful target vein however can limit elbow movement for the patient.²⁶
 - Avoid attempting insertion in vessels with a diameter smaller than 2mm, as success rates are significantly reduced.



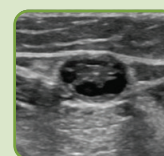
Vessels to avoid



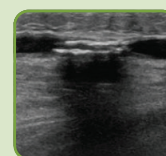
Thrombosed, occluded vessel



Thick walled with phleboliths



Recanalised thrombosis



Calcified vessels

35

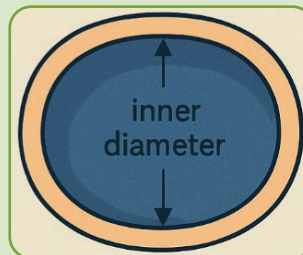
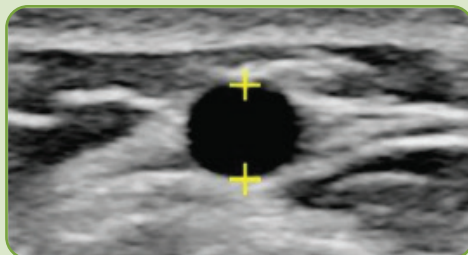




Determining the appropriate PIVC size and gauge

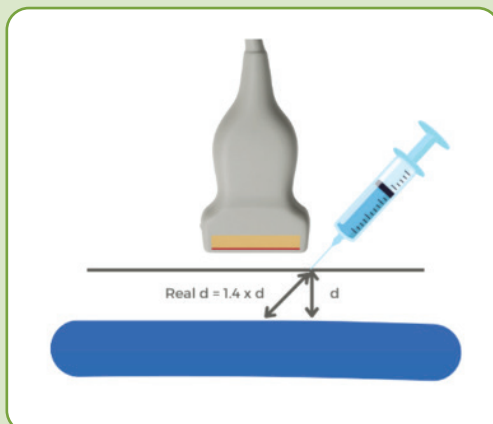
Selecting the appropriate size and gauge of the PIVC is central to ensuring effective therapy and minimising complications. The following guidelines should be considered:

- **Use the smallest gauge PIVC that will accommodate the prescribed therapy and patient needs:** This approach reduces the risk of phlebitis and other complications.^{7,24,28,36} For example, a 22-gauge PIVC is often sufficient for most infusions and is less traumatic to the vein. This compares to larger gauge PIVC (e.g. 14 or 16 gauge) may be necessary for rapid fluid replacement or trauma situations, while smaller gauges (e.g. 24 or 26 gauge) are suitable for paediatric patients or those with DIVA.
- **Measure the inner-to-inner wall diameter of the vessel when applying minimal pressure:** This helps to select an appropriate PIVC.^{32,35} The chosen PIVC size should be the luminal diameter of the vessel to ensure proper fit and reduce the risk of complications, such as thrombus formation.³⁵

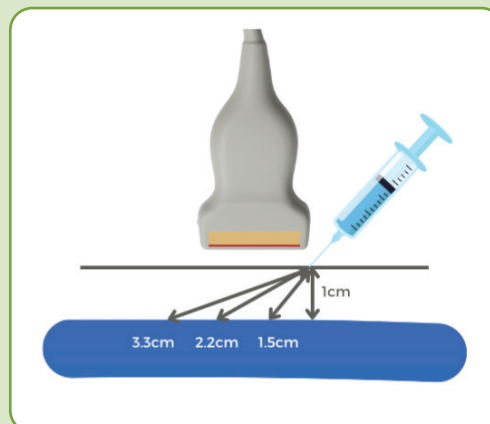


- **Select PIVC length based on the total distance it will need to travel to enter the vein:** The sonographer must also factor in sufficient length of the PIVC to be secured within the vein, 2/3rd of PIVC length is recommended.¹⁸ This ensure that the PIVC remains stable and reduces the risk of dislodgement.

Depth of vessel



The distance to reach the vein depends on the insertion angle. When the insertion angle is 45 degrees, the distance to reach the vein is equal to d multiplied by 1.4.¹⁹



Shallow angle of insertions results in a longer pathway to reach the vein, leaving a larger portion of the PIVC outside the vein, which can lead to failure. In comparison, angled insertions shorten the distance to the vein, increasing the portion of PIVC within the vein lumen.¹⁹





Steps for effective skin preparation before PIVC insertion

Proper skin preparation is essential to minimise the risk of infection and ensure a successful USGPVC insertion. Follow these steps to prepare the skin effectively:

Initial Cleaning:

- **If the skin is visibly soiled, clean the area with soap and water before applying any antiseptic solution:** This helps remove dirt and debris that could interfere with the antiseptic's effectiveness.^{24,28}
- **Clip hair if needed:** This ensures better securement of your PIVC dressing and the skin.²⁸

Antiseptic Solution Selection:

- **Choose an appropriate antiseptic solution for skin preparation:** The recommended options include:
 - **Chlorhexidine gluconate:** A 2% chlorhexidine gluconate solution in 70% isopropyl alcohol is highly effective against a broad spectrum of microorganisms.^{24,28,29}
 - **Povidone-iodine:** A 10% povidone-iodine solution is an alternative that also provides broad-spectrum antimicrobial activity.^{24,28,29}

Application Technique:

- **Apply antiseptic:** Using an applicator, apply the antiseptic solution using an aseptic non-touch technique (ANTT) to the insertion site.^{24,28,29}
- **Coverage area:** Use concentric circles to cover an area of skin approximately 10cm x 10cm, for at least 30 seconds.²⁸

Drying Time:

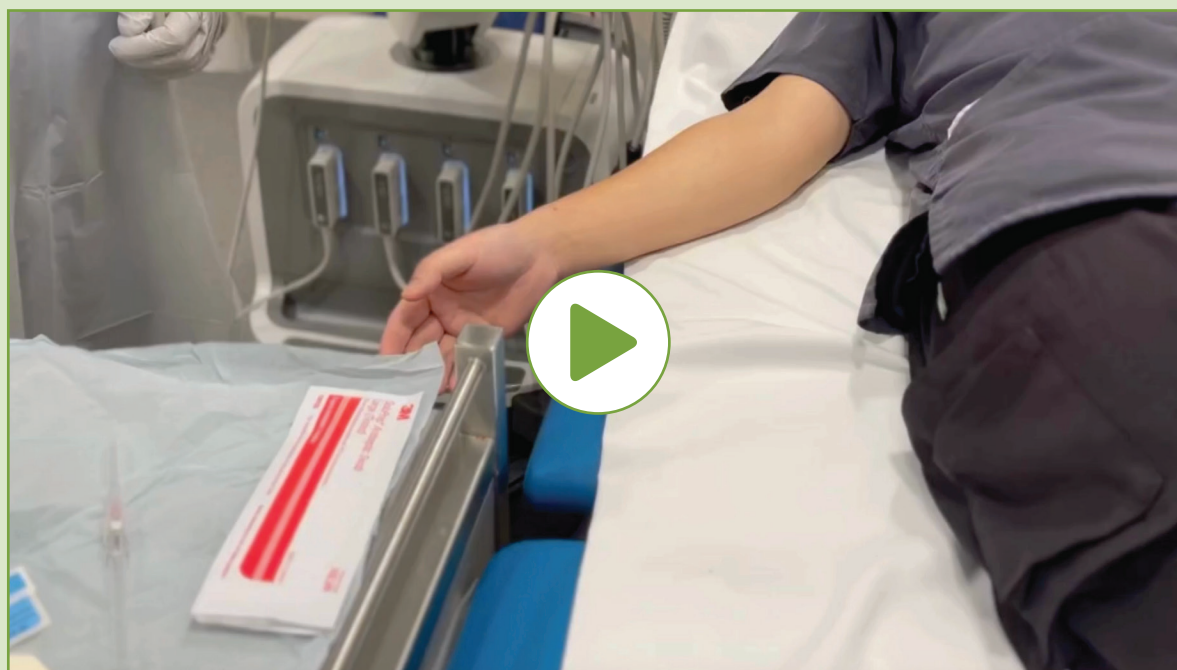- **Allow the antiseptic solution to air dry completely before proceeding with the insertion:** This step is crucial for maximising the effectiveness of the antiseptic.^{7,24,28}

Aseptic technique:

- **Gloves:** Wear gloves during the procedure to maintain aseptic technique.
- **Avoid recontamination:** Once the skin has been prepped, avoid touching the insertion site or any key part or key site of the aseptic field.^{6,7,24,28} If contact is necessary, use gloves and maintain aseptic technique.

Special Considerations:

- **Allergies and sensitivities:** Assess the patient for any known allergies or sensitivities to antiseptic solutions.^{7,24} If the patient has a history of allergic reactions, consider using an alternative antiseptic.
- **Paediatric patients:** For children, use antiseptic solutions that are safe and appropriate for their age and skin condition. Follow institutional guidelines and manufacturer recommendations.



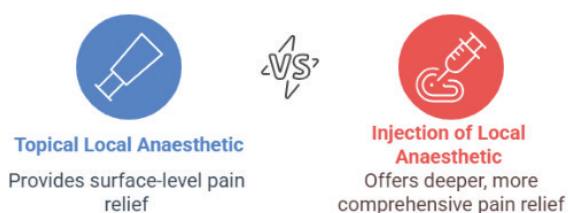

Pain management strategies for USGPIVC insertion

Many patients find PIVC insertion painful.^{17,39}

- Inadequate pain relief not only causes discomfort but may also lead to anxiety about future treatments and deter patients from seeking medical care.³⁹
- Fear of the procedure can trigger postural hypotension and vasoconstriction, reducing venous access and making PIVC insertion more difficult.³⁹ Consider positioning the patient in a supine (lying flat) position.
- Educating patients about the procedure, its necessity, and what to expect can reduce fear and anxiety by providing a sense of control and understanding.^{37,38}
- Engaging the patient in conversation or providing visual distractions can provide effective pain management.^{37,38}
- Research has found that the pain of local anaesthetic application is considerably less than that of cannulation.³⁹ Therefore consideration should be given for local anaesthetic prior to insertion of PIVC, depending on state-based legislation.

Pain management strategies USGPIVC insertion



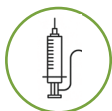Topical local anaesthetic

- Topical local anaesthetic, such as lignocaine 2.5% with prilocaine 2.5% or eutectic mixture of local anaesthetics (EMLA cream), can be applied by sonographers 60 minutes before insertion to numb the skin.^{24,40,48}
- EMLA cream is particularly useful for children.⁴⁸
- While effective, these creams can leave a lipid residue that may create a focus for microbial growth, therefore it should be removed with soap and water before skin preparation.^{24,48}

Injection of local anaesthetic

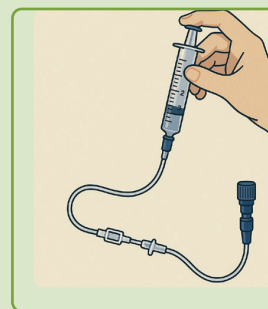
- Intradermal injection of local anaesthetic, such as lidocaine (lignocaine 1% or xylocaine 1%), offers rapid and targeted pain relief.^{6,28}
- This method requires informed consent, allergy screening, and adherence to local legislation.⁵¹ Patients should be informed that administration of local anaesthetic may cause some discomfort or a brief stinging sensation.
- See [Appendix 3: Central Government, States, and Territories drug and poison regulation](#).
- The exact dosage may vary depending on the patient's age, weight and condition, and should be recorded in the patient's medical file.
- Note that lidocaine may cause vasoconstriction, potentially affecting vein visibility.⁵²





PIVC insertion steps

- Aseptically prepare IV flush and prime extension set.²⁸
- Apply the tourniquet.^{28,48}
- Perform hand hygiene and don gloves if touching key parts and key sites.^{6,26,28,48}
- Use single-use equipment for each PIVC insertion. Ensure that all equipment, including the ultrasound transducer, is properly cleaned or disinfected, and covered with a suitable sterile cover (refer to manufacturer recommendations).²⁶ Use sterile ultrasound gel during insertion.
- Maintain aseptic technique throughout the procedure to prevent microorganisms on hands, surfaces or equipment from being introduced.^{15,24,29,46}
- Use the dominant hand to control the needle tip, while the non-dominant hand manages the ultrasound transducer to maintain optimal visualisation. Pierce the skin at a 35-45° angle above the entry site.^{19,44} Navigate it through the tissue into the target vessel.^{25,31} Insert the PIVC, visualise 'flashback' at the hub, advance the plastic cannula, and withdraw the stylet.^{7,18,26,28,48}
- Release the tourniquet, attach the extension set with a needleless injection cap, flush the PIVC with 0.9% Sodium Chloride.^{7,28} Using ultrasound guidance to observe the saline flush as bubbles in the lumen of the vein.¹⁹ Secure the PIVC with transparent semipermeable membrane (TSM) dressing.^{5,24,50} Record the insertion date and time on the dressing.²⁵
- Remove gloves, perform hand hygiene, return the patient to a comfortable position.²⁸



Post insertion care and documentation

- Dispose of needles and other sharps immediately after use in designated sharps containers.⁴⁶ Do not recap needles to prevent needlestick injuries.⁴⁶ This helps prevent the transmission of blood-borne disease to healthcare workers.^{15,46}
 - 40% of sharps injuries occur after use and before disposal of a sharp device, 41% occur during use of the sharp device on the patient, and 15% occur during or after disposal of the sharp device.⁴⁶
 - Hollow bore needles, such as those that are used during PIVC insertion, are a particular concern as they are likely to contain residual blood.⁴⁶
- Dispose of waste appropriately, clean the trolley with alcohol/detergent wipes and perform routine hand hygiene.^{28,46,48}
- Educate patients on the importance of keeping the insertion site clean and dry. Provide instructions on how to monitor for signs of infection and when to seek medical attention.
- Document the reason for insertion, length and gauge of PIVC, location, date and time, aseptic technique used, failed attempts, escalation plans, and the name, designation, and signature of the proceduralist.^{6,7,28}
- Perform post procedure cleaning of the transducer.⁴⁵ [See Ensuring safe reprocessing of ultrasound transducers](#)
- The ongoing review and considerations for replacement of PIVC should be maintained by the treating physician.

Appendix 3: Central Government, States, and Territories drug and poison regulation

Australian Capital Territory:

Medicines, Poisons and Therapeutic Goods Act 2008 and the Medicines, Poisons and Therapeutic Goods Regulation 2008

New South Wales:

Poisons and Therapeutic Goods Regulation 2008

Northern Territory:

Medicines, Poisons and Therapeutic Goods Act 2012

Queensland:

Health (drugs and poisons) regulation 1996

South Australia:

Controlled Substances Act 1984 and the Controlled Substances (Poisons) Regulations 2011

Tasmania:

Poisons Act 1971 and the Poisons Regulations 2018

Victoria:

Drugs, Poisons and Controlled Substances Act 1981 and the Drugs, Poisons and Controlled Substances Regulations 2017

Western Australia:

Medicines and Poisons Act 2014 and the Medicines and Poisons Regulations 2016

New Zealand:

Misuse of Drugs Regulations 1977 and Medicines Regulations 1984

Appendix 4: Acknowledgements

The ASA would like to thank all those who have generously given their time and shared their expertise to support and inform this guideline. Key stakeholder input was sourced from a number of professional bodies and associations, both public and private employers, ASA SIG, ASA SPAC, and NZ SAG.

The ASA would like to acknowledge Christopher Gilmore (FASA) for his valuable contributions to this guideline. His generous provision of instruction videos and images significantly enhanced the educational content. His expertise and support are greatly appreciated.

Level 2, 93–95 Queen Street
Melbourne VIC 3000, Australia

T | +61 3 9552 0000

E | researchandstandards@sonographers.org

www.sonographers.org

