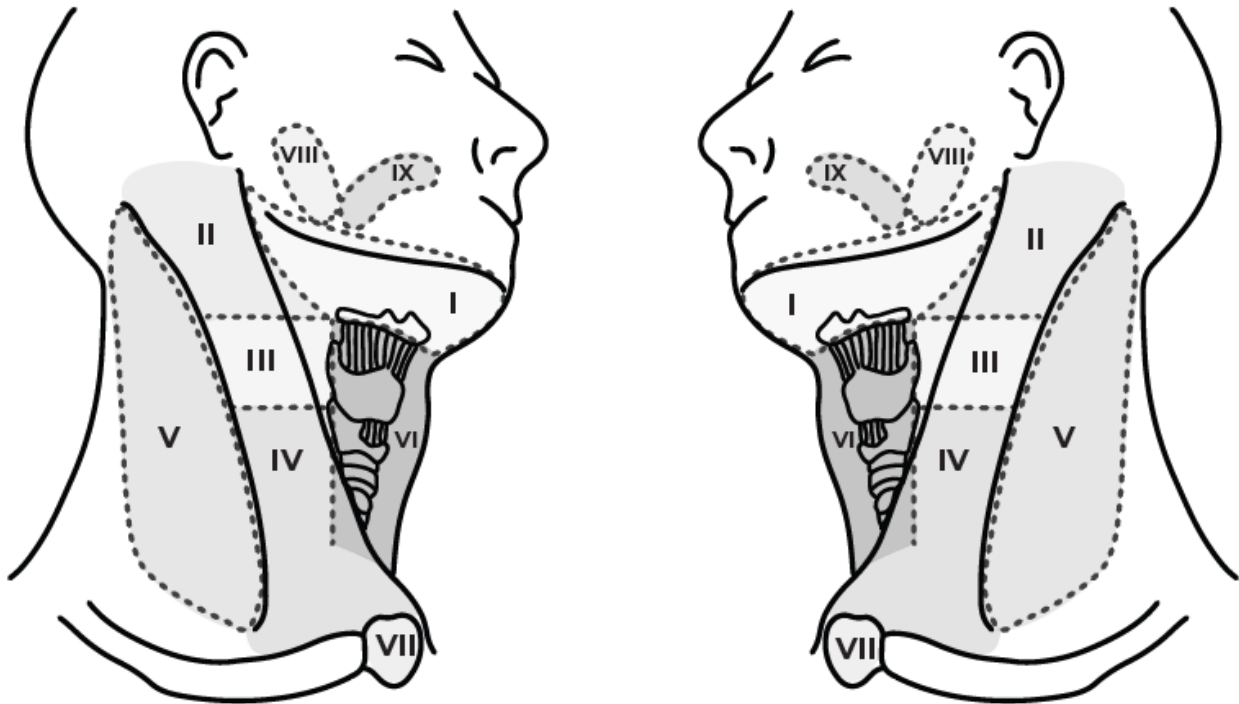


## NECK LYMPH NODE ULTRASOUND



Sonographic features that help identify abnormal nodes include shape (round), absent hilus, intranodal necrosis, reticulation, calcification, matting, soft tissue oedema and peripheral vascularity.

Patient History: .....

COMMENT (location, size, number and features): .....

**SONOGRAPHER:**