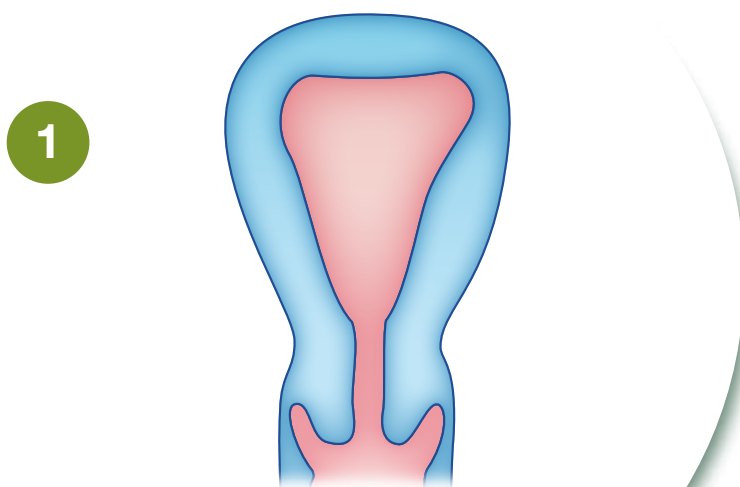


THE SONOGRAPHER'S

QUICK REFERENCE GUIDE TO CONGENITAL UTERINE ANOMALIES

asa
australasian
sonographers
association

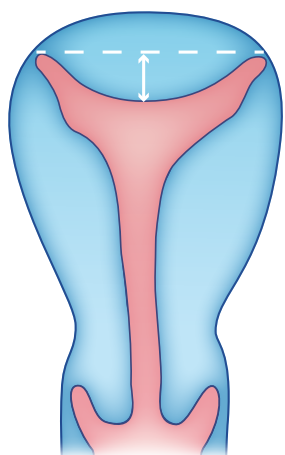
CONGENITAL UTERINE ANOMALIES



1

NORMAL UTERUS

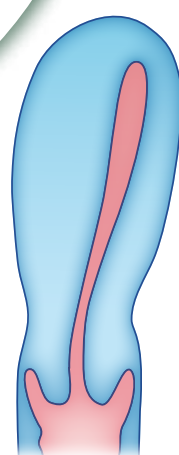
- Fundal uterine contour: rounded
- Fundal endometrial cavity: flat
- Single cervical cavity



2

ARCUATE UTERUS

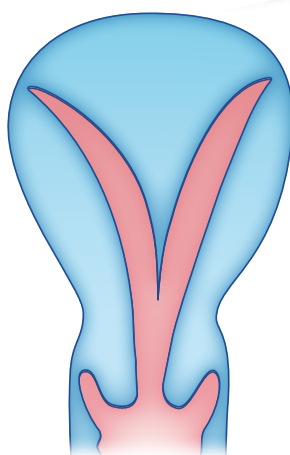
- Fundal uterine contour: rounded
- Fundal endometrial cavity: mild indentation <10mm
- Single cervical cavity



3

UNICORNUATE UTERUS

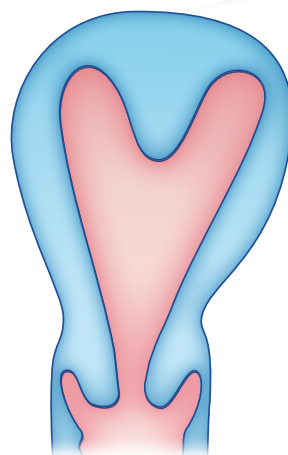
- Fundal uterine contour: rounded but smaller than normal uterus
- Endometrial cavity overall reduced in size
- Rudimentary horn may or may not be present, may or may not communicate with cavity
- Strong association with renal anomalies



4

SEPTATE UTERUS

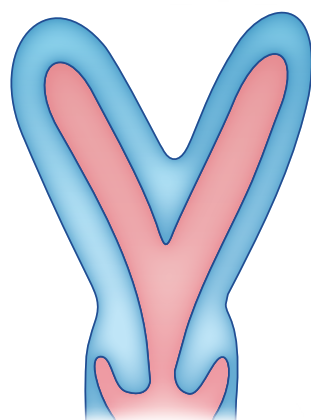
- Fundal uterine contour: flat or slightly indented (<10mm)
- Endometrial cavity is divided by a septum that extends to the internal os
- Single cervical cavity



5

SUBSEPTATE UTERUS

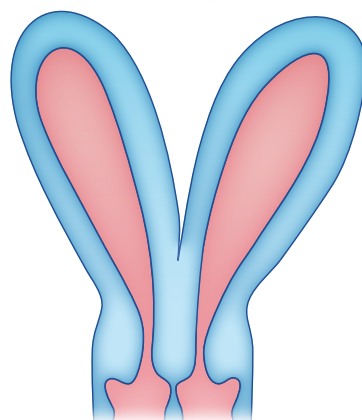
- Fundal uterine contour: flat or slightly indented (<10mm)
- Endometrial cavity is divided by a septum that extends >10mm but not to the internal os
- Single cervical cavity



6

BICORNUATE UTERUS

- Fundal uterine contour is concave (>10mm) forming a heart shape
- Endometrial cavity within each uterine contour
- Can present with a single cervical cavity (unicollis) or duplicated cervix (bicollis)



7

DIDELPHYS UTERUS

- Fundal uterine contour has a deep fundal cleft extending between each horn, reaching the vaginal vault with a single fallopian tube
- Endometrial cavity within each uterine horn and a cervical cavity
- Can present with two vaginal vaults or a single vaginal vault with intact septum

All views in coronal plane



© 2016 Australasian Sonographers Association Ltd. This poster remains the property of the Australasian Sonographers Association. No part of it may be reproduced without permission. Anatomical variations may exist.

References:

1. Rumack: Diagnostic Ultrasound, 3rd edition, Vol.1.

2. Callen: Ultrasonography in O&G, 5th edition.

3. Human Reproduction Update (2008), 14(5): 416-429.

4. Salim: Human Reproduction; A comparative study of the morphology of congenital uterine anomalies in women with and without a history of recurrent miscarriage. Vol 18, no. 1 pp 162-166 (2003).

www.a-s-a.com.au