a healthier world through
sonographer expertise

ASA Endometriosis Guidelines Image Gallery

DRAFT

© 2026 Australasian Sonographers Association Ltd. Disclaimer: The information in this publication is current when published and is general in nature; it does not constitute professional advice. Any views expressed are those of the author and may not reflect ASA's views. ASA does not endorse any product or service identified in this publication. You use this information at your sole risk and ASA is not responsible for any errors or for any consequences arising from that use. Please visit www.sonographers.org for the full version of the Australasian Sonographers Association publication disclaimer.

Level 2, 93–95 Queen Street
Melbourne 3000 VICTORIA

T +61 3 9552 0000
F +61 3 9558 1399

www.sonographers.org
2026

Uterus

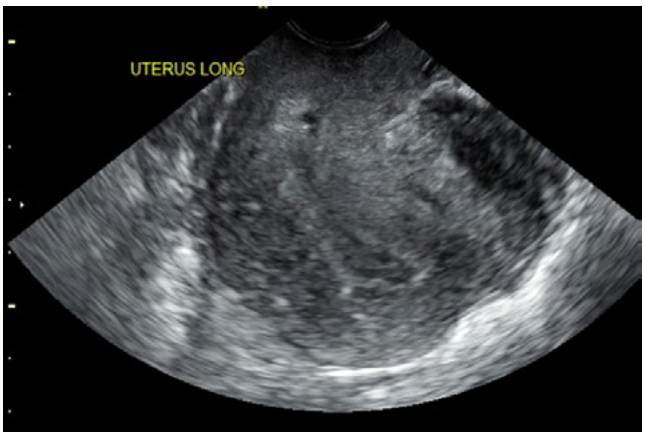

Image 1: Anteverted retroflexed uterus.

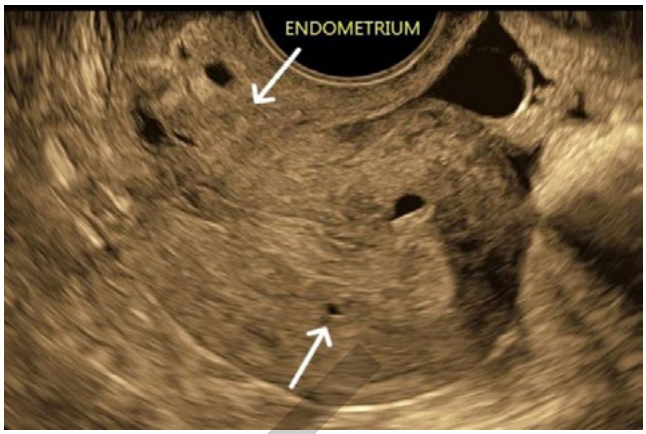

Image 2: Hyperechoic islands and myometrial cysts are direct sonographic features of adenomyosis.

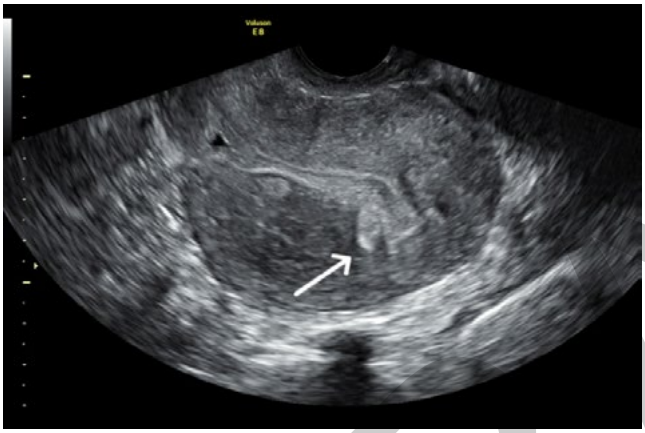

Image 3: Echogenic subendometrial lines or buds projecting into the adjacent myometrium, a characteristic sonographic feature of adenomyosis.

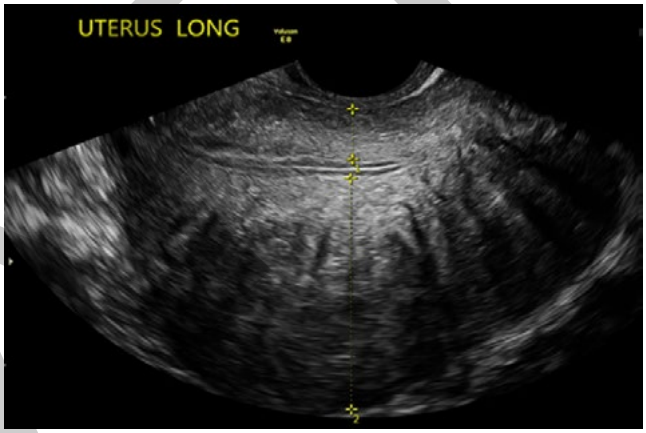

Image 4: Ultrasound image of posteriortoanterior uterine wall thickness ratio > 1, suggesting asymmetry associated with adenomyosis.

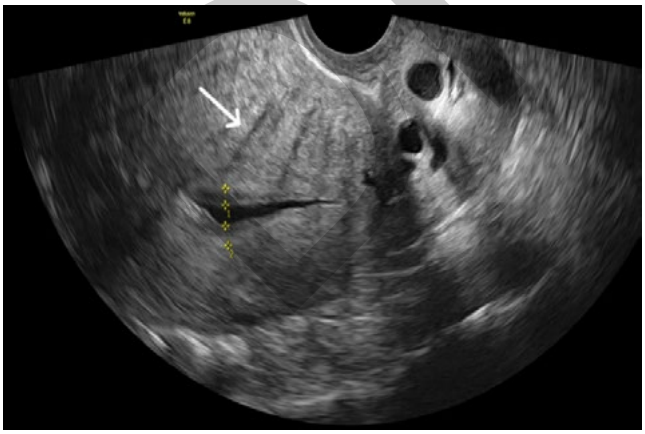

Image 5: Fanshaped acoustic shadowing of the myometrium, a characteristic sonographic feature of adenomyosis.

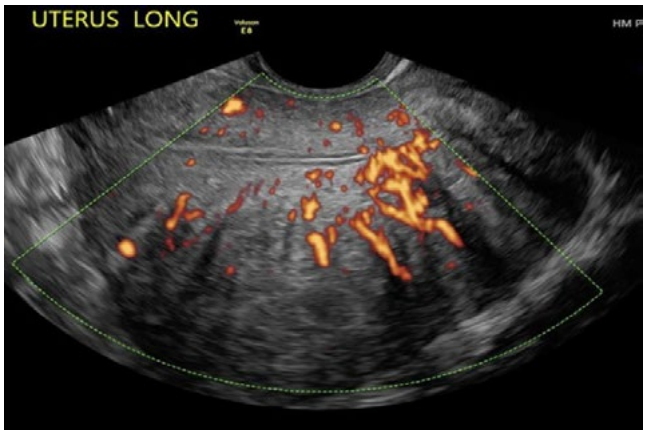

Image 6: Translesional vascularity traversing areas of abnormal myometrium on power Doppler, supporting a diagnosis of adenomyosis.

DRAFT

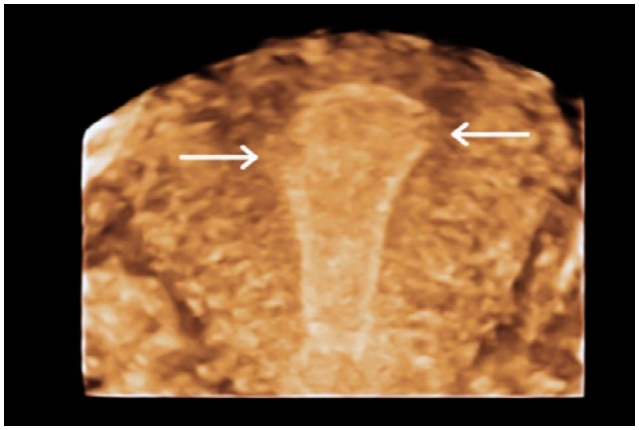

Image 7: Irregular outline of the endometrial cavity with loss of clear myometrial junctional zone in the fundal region.

Ovaries

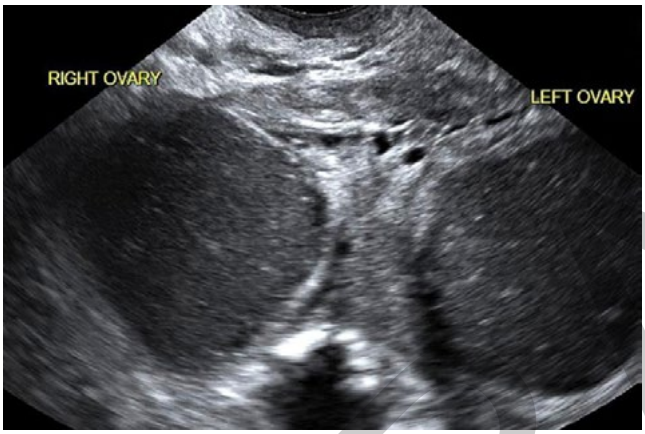

Image 8: “Kissing ovaries” fixed in the midline, a feature strongly associated with advanced endometriosis.

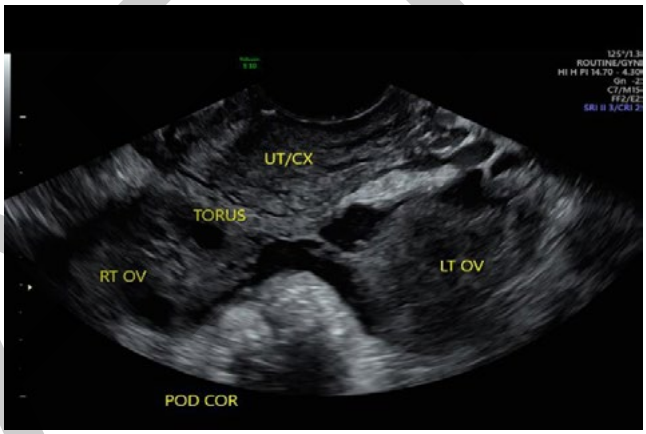

Image 9: Ovaries fixed together in the posterior compartment.

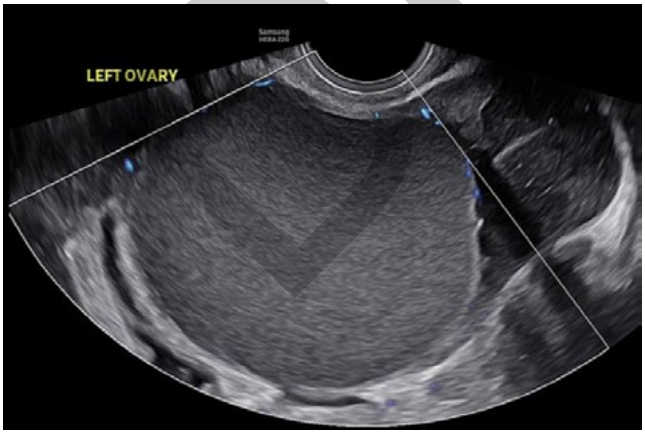

Image 10: Unilocular cysts are a feature of ovarian endometriomas.

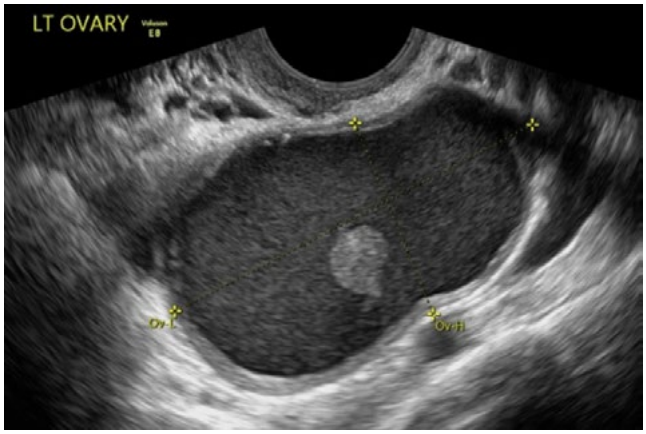

Image 11: Diffuse low-level internal echoes giving a “ground-glass” appearance, a hallmark sonographic feature of an endometrioma.

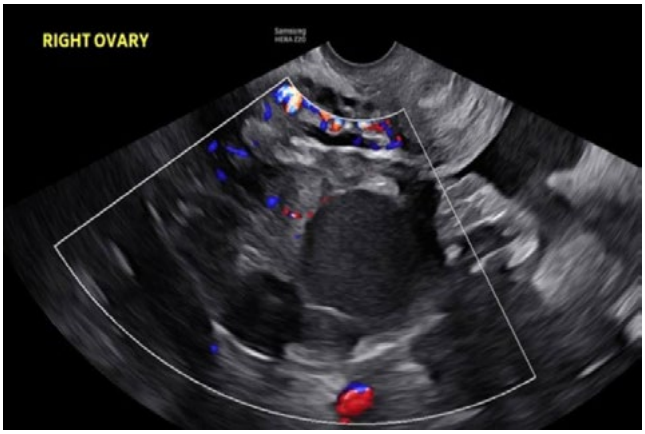

Image 12: Low-level homogeneous internal echoes within a cystic ovarian lesion, absence of internal vascularity, classic features of an endometrioma.

Hydrosalpinx and haematosalpinx

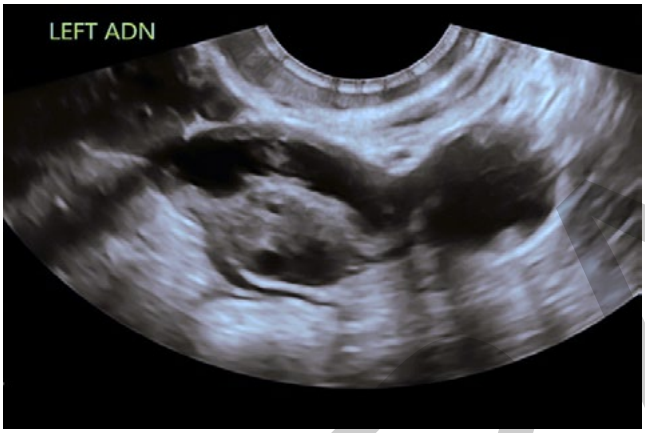

Image 13: Transvaginal ultrasound image demonstrating a dilated, fluid-filled fallopian tube (hydrosalpinx).

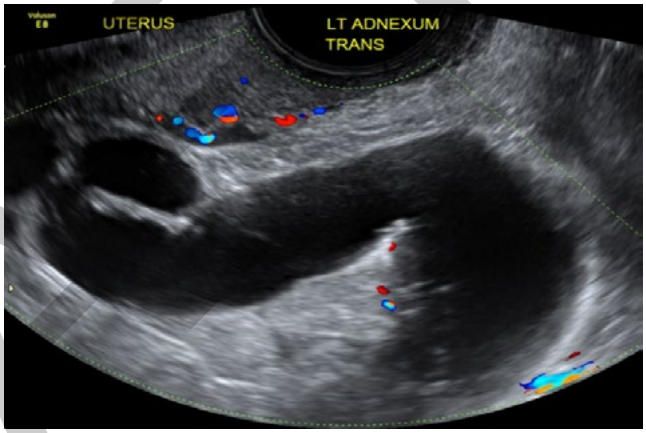

Image 14: Transvaginal ultrasound image demonstrating a fluidfilled fallopian tube, consistent with hydrosalpinx.

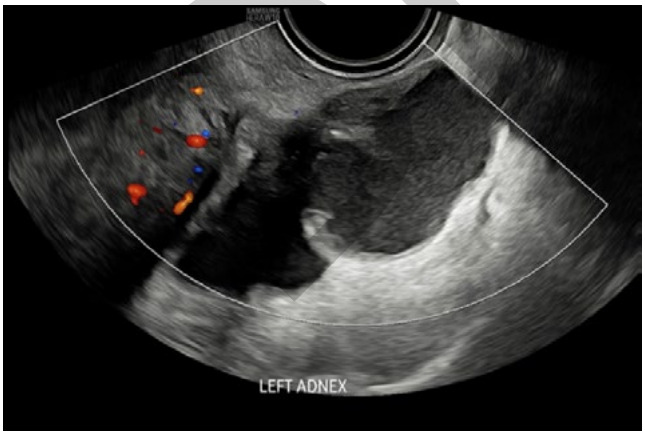

Image 15: Transvaginal ultrasound image demonstrating a dilated fallopian tube containing echogenic fluid consistent with haematosalpinx.

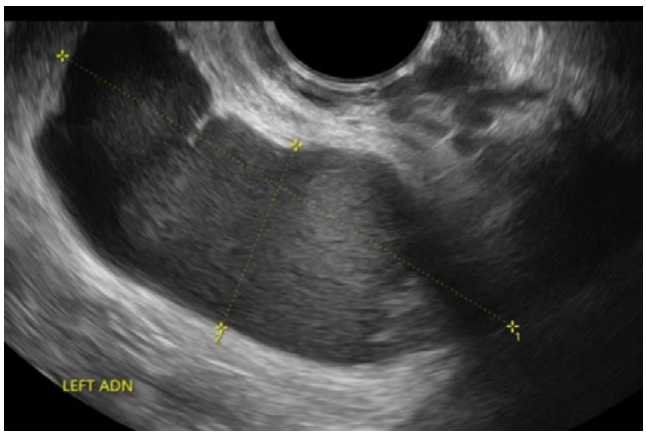

Image 16: Transvaginal ultrasound image demonstrating haematosalpinx, can be associated with endometriosisrelated tubal obstruction.

DRAFT

Posterior compartment

Positive sliding sign

Video 1: Positive sliding sign showing uterus moving freely against the bowel.
LINK: https://vimeo.com/1166225232?fl=tl&fe=ec

Video 2: Positive posterior compartment sliding sign with independent movement of the uterus and bowel.
LINK: https://vimeo.com/1166225370?fl=tl&fe=ec

Negative sliding sign

Video 3: Negative sliding sign suggestive of adhesions.
LINK: https://vimeo.com/1166225283?fl=tl&fe=ec

Posterior compartment adhesions

Video 4: Posterior compartment demonstrating superficial adhesions
LINK: https://vimeo.com/1166225215?fl=tl&fe=ec

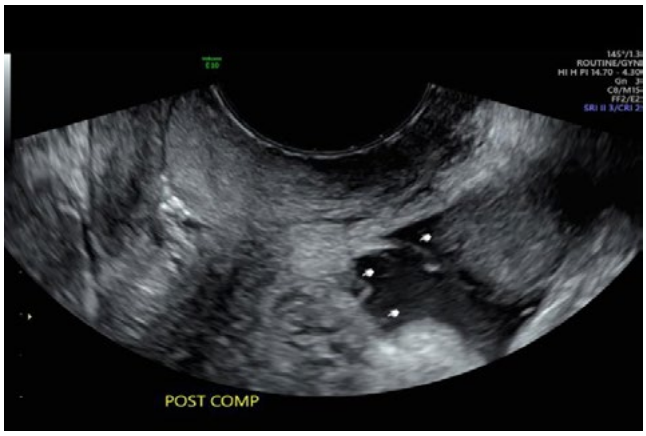

Image 17: Adhesions noted adjacent to the ovary.

DRAFT

Uterosacral ligaments (USL)

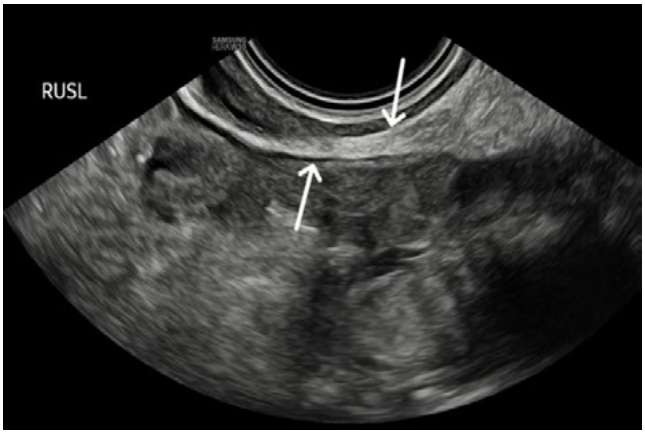

Image 18: Transvaginal ultrasound image demonstrating a normal right USL without thickening or nodularity.

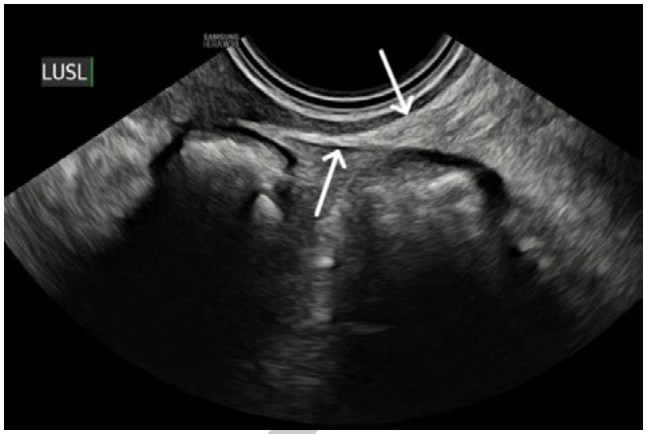

Image 19: Normal sonographic appearance of the left USL on transvaginal ultrasound.

Video 5: Assessment of the USL in the posterior fornix.
LINK: **https://vimeo.com/1166224831?fl=tl&fe=ec**

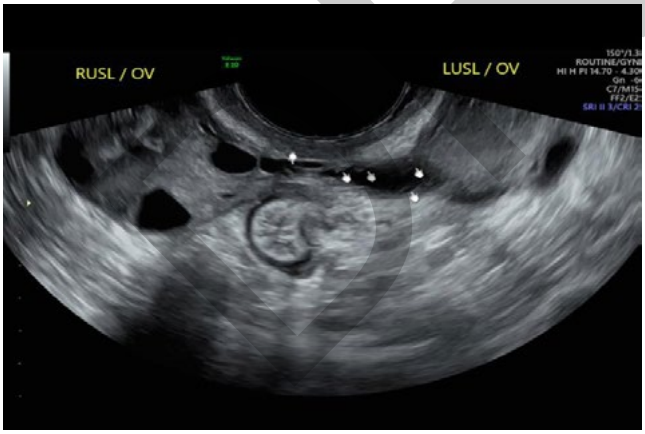

Image 20: USL demonstrating nodularity.

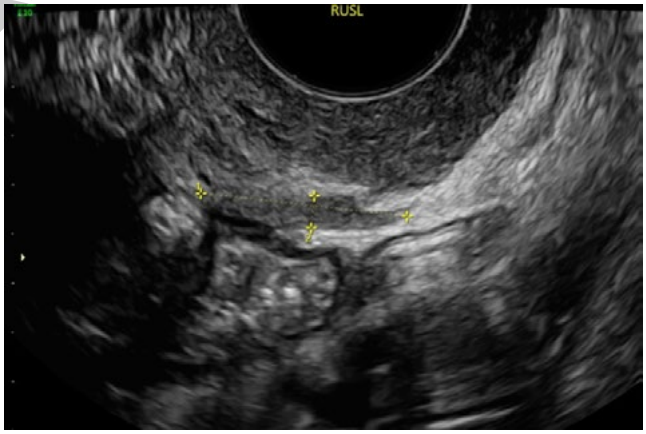

Image 21: Endometriosis lesion within the right uterosacral ligament, consistent with deep endometriosis.

DRAFT

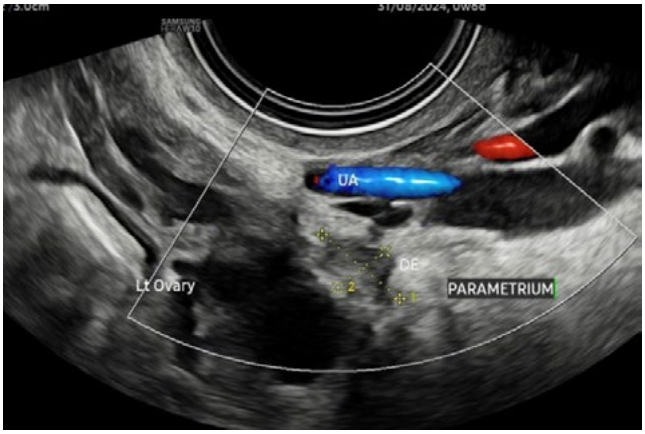

Image 22: Transvaginal ultrasound image demonstrating a hypoechoic lesion within the left parametrium.

Image 23: Transvaginal ultrasound image demonstrating a hypoechoic lesion involving the right uterosacral ligament and adjacent right parametrium.

Torus uterinus

Image 24: Torus uterinus is noted as a fibromuscular ridge on the posterior cervix, seen with adjacent left ovarian endometrioma.

Image 25: Transvaginal ultrasound image demonstrating a hypoechoic lesion involving the torus uterinus, consistent with endometriosis.

Video 6: Adhesions noted in the region of the torus uterinus and the USL.
LINK: **https://vimeo.com/1166225189?fl=tl&fe=ec**

DRAFT

Rectovaginal septum

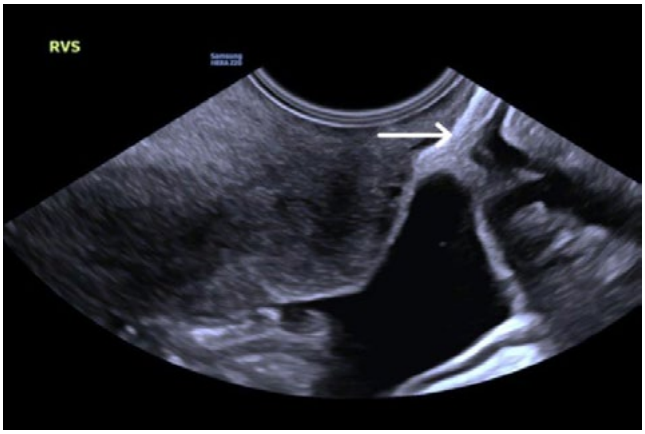

Image 26: Transvaginal ultrasound image demonstrating the rectovaginal septum.

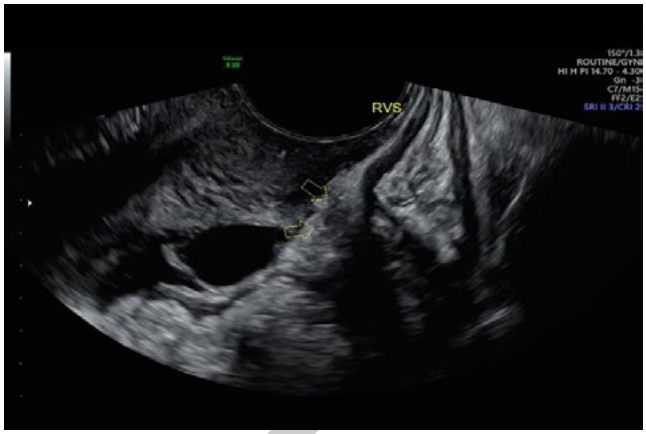

Image 27: RVS lesion noted between the vagina and the rectum.

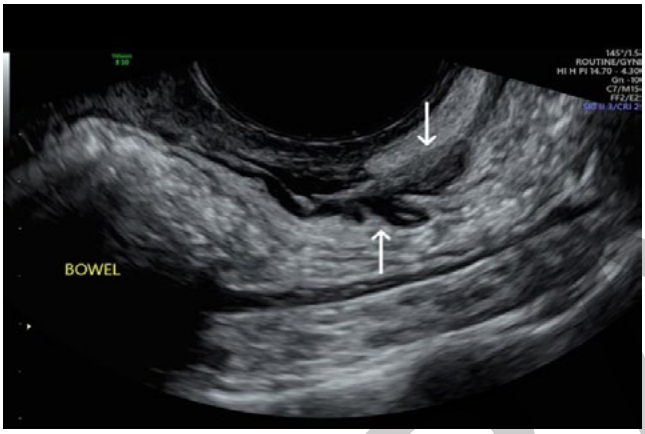

Image 28: RVS lesion with involvement of the bowel wall

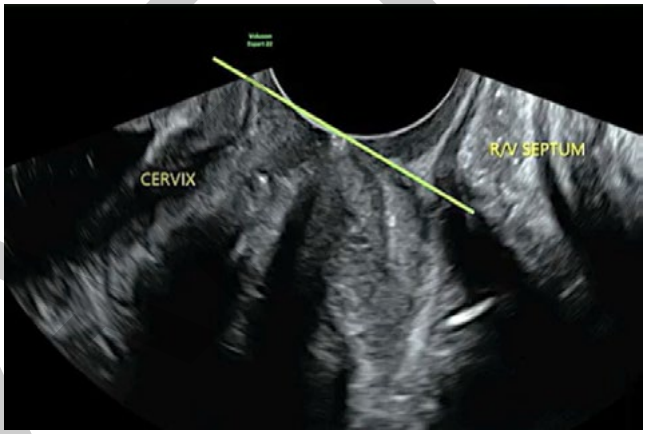

Image 29: RVS is found by using an imaginary line along the lower border of the posterior cervical lip.

Rectum, rectosigmoid junction, and sigmoid

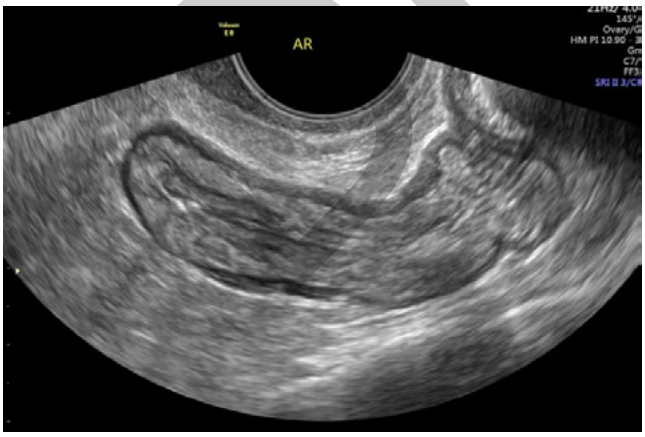

Image 30: Normal bowel wall appearance on transvaginal ultrasound.

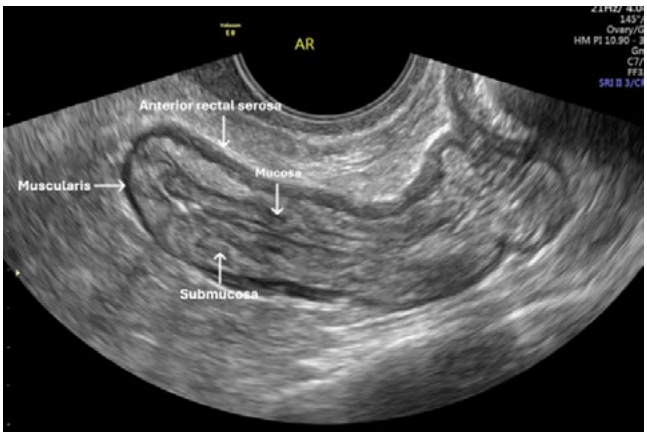

Image 31: Anatomy of the bowel wall.

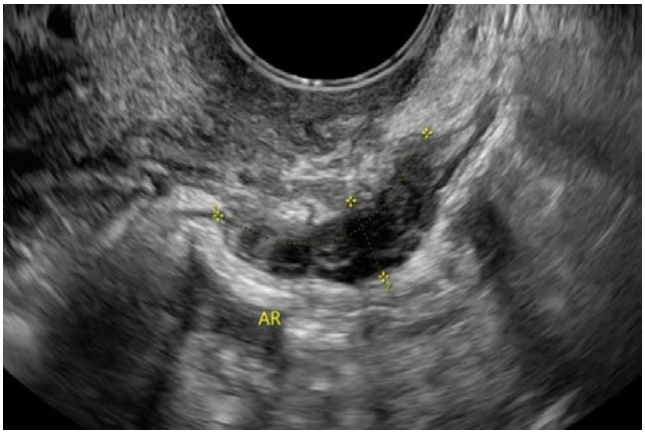

Image 32: Transvaginal ultrasound image demonstrating a hypoechoic bowel wall lesion, consistent with deep endometriosis.

Anterior Compartment

Bladder

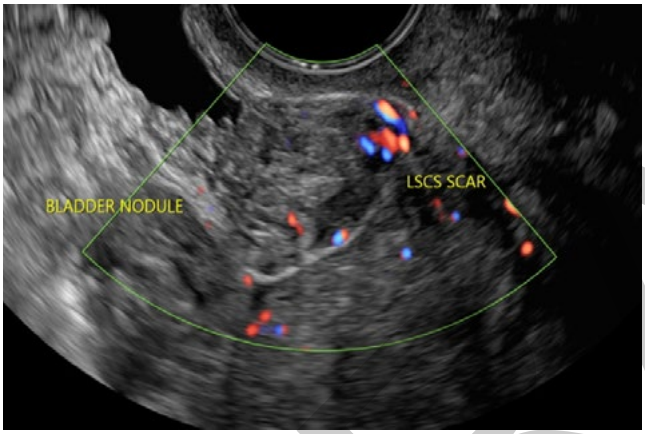

Image 33: Transvaginal ultrasound image demonstrating a bladder wall lesion consistent with endometriosis.

Video 7: Anterior compartment positive sliding sign.
LINK: **https://vimeo.com/1166225165?fl=tl&fe=ec**

Superficial Endometriosis

Video 8: Superficial endometriosis noted in the anterior compartment.
LINK: **https://vimeo.com/1166225142?fl=tl&fe=ec**

Image 34: Anterior uterine serosal lesion.

DRAFT

DRAFT

Level 2, 93–95 Queen Street
Melbourne VIC 3000, Australia

T | +61 3 9552 0000

E | researchandstandards@sonographers.org

www.sonographers.org

asa
australasian
sonographers
association