

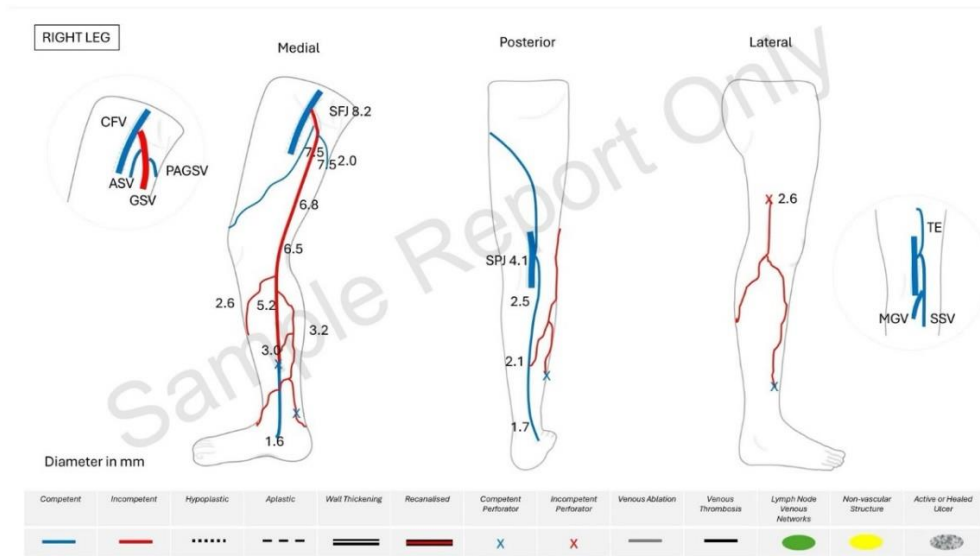
Example of Sonographer report (colour coded version)

(reproduced with permission from Western Sydney Vascular)

Patient ID: 999000012
Exam date: 21/05/2024

Extremity Venous Duplex

Patient: **Trainee TESTING**, DOB: 13/05/1942



Indication Right Leg Varicose Veins, Swelling and Hyperpigmentation

Comment On the right side, the common femoral vein, femoral vein, and popliteal vein are patent and competent with no evidence of valvular incompetence or venous obstruction.

The sapheno-femoral junction is incompetent.

The great saphenous vein is incompetent from the groin to the mid-calf, becoming competent at the distal calf below the level of a re-entry para-tibial perforator.

The sapheno-popliteal junction is located 2 cm above the popliteal crease with no evidence of reflux.

The small saphenous vein is competent throughout the calf, and its thigh extension, connecting with the posterior accessory great saphenous vein, is also competent.

Above the knee, the anterior saphenous vein in the upper thigh shows no evidence of reflux. Tributary veins in the anterolateral thigh drain into the anterior saphenous vein. An incompetent lateral thigh perforator, located 15 cm above the popliteal crease, feeds the varicose tributary veins in the distal lateral thigh.

Below the knee, both the anterior arch vein and posterior arch vein are incompetent, with

reflux originating from the great saphenous vein. A re-entry posterior tibial perforator, located 12 cm above the medial malleolus, drains the reflux from the posterior arch vein. Incompetent tributary veins in the lateral calf are associated with the incompetent lateral thigh perforator and its tributaries. A lateral calf perforator located at 15cm below the popliteal crease drains the reflux flow from the lateral calf tributaries.

Conclusion

Normal deep vein system.
Great saphenous vein incompetence with calf tributaries associated.
Normal small saphenous vein system.
Incompetent lateral thigh perforator identified as a source of reflux.

Sonographer

Vascular surgeon

Example of Sonographer report (no colour coding, suitable when no colour reproduction available)

(reproduced with permission from Nepean Vascular Laboratory)

VASCULAR LABORATORY

Address: xxx

Phone: 02 xxxx xxxx Fax: 02 xxxx xxxx Email: xxx@xxx.com.au

Vascular Ultrasound Report

Patient Details:

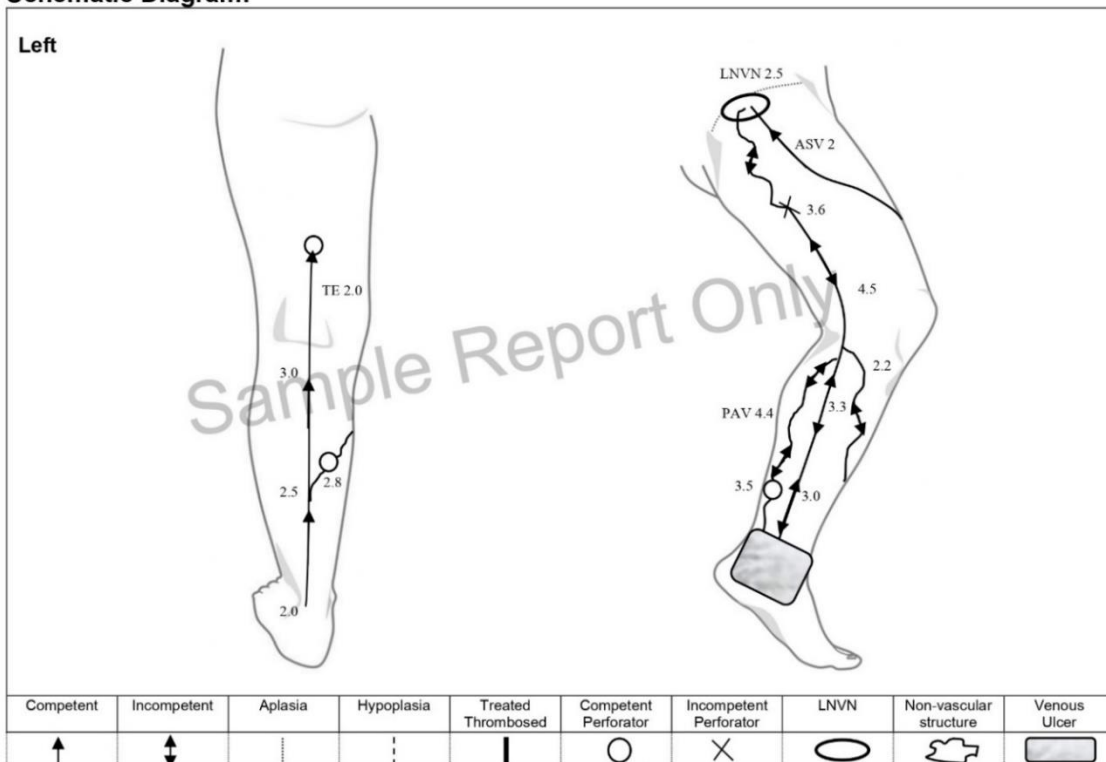
Surname:	ABC	First Name:	XYZ
Date of birth:	10/04/1945	Date of the examination	11/06/2024
Referred by:	Dr -	Time of the examination	2:30pm
Sonographer:	-		

Study: Left Leg Venous Insufficiency Ultrasound Examination

Clinical indication: Left leg recurrent varicose veins and venous ulcer in the ankle area (>3months)

Medical history: 2018 – Sapheno-femoral junction ligation and great saphenous vein stripping surgery

Schematic Diagram:



Report:

In the left leg, the common femoral vein, femoral vein and popliteal vein are patent and competent with no evidence of venous obstruction and valvular incompetence.

The sapheno-femoral junction and great saphenous vein proximal-mid thigh segment are not visualised, in keeping with prior surgery. There is an incompetent thigh perforator (\varnothing 3.6mm) located at 18cm above the knee crease, feeding the great saphenous vein remnant.

There is no sapheno-popliteal junction visualised, and small saphenous vein continues up, joining with the thigh extension of the small saphenous vein, with no reflux flow detected throughout.

Above the knee, a competent anterior saphenous vein is present at the upper thigh with no evidence of venous reflux. Neovascularisation is noted in the groin region associated with incompetent lymph node venous networks. Incompetent tributary veins are found in the proximal thigh carrying reflux from the groin varices to the great saphenous vein remnant. The thigh extension of the small saphenous vein is seen with its flow drained via a posterior thigh perforator.

Below the knee, incompetent tributary veins are identified in both posteromedial and anteromedial calf, both travelling down to the ulcerated area and associated with the great saphenous vein incompetence. At 12cm above the medial malleolus, there is posterior tibial perforator (\varnothing 3.5mm) draining reflux from the posterior arch vein. A medial gastrocnemius re-entry perforator (\varnothing 2.8mm) is also noted at 8cm below the knee crease, draining the reflux from the posteromedial calf tributaries.

Conclusions:

Left Leg – Normal deep venous system and small saphenous vein. Incompetent lymph node venous networks and mid-thigh perforator which are responsible for the great saphenous vein incompetence and recurrent varicosities in the calf.

Reported by,
























Dr –
FRAC, Vascular, Endovascular and Transplant Surgeon

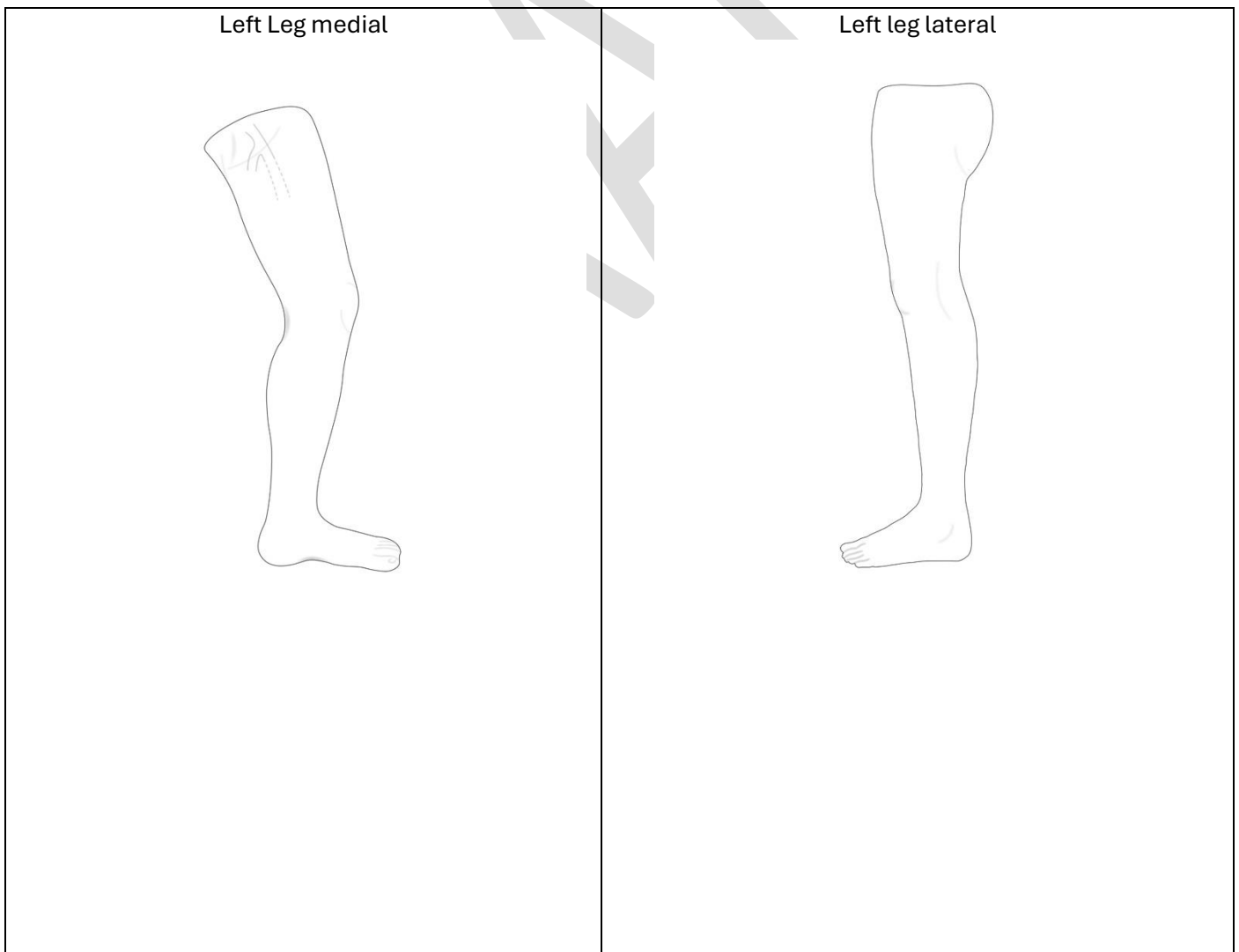
Finalised on Tuesday 11 June 2024

Sample Report Only

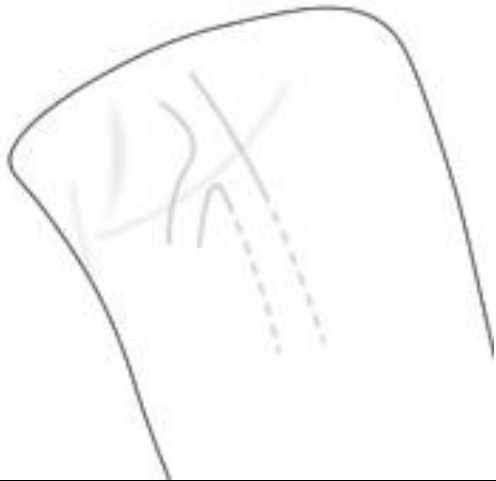Material that sonographers can use to develop departmental worksheets

(Reproduced with permission from Western Sydney Vascular and Nepean Vascular Laboratory)

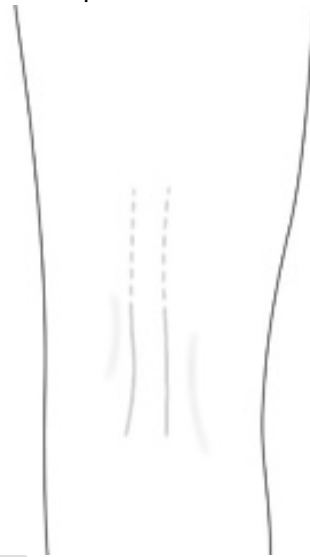Key for colour worksheet												
Competent	Incompetent	Hypoplastic	Aplastic	Wall Thickening	Recanalised	Competent Perforating vein	Incompetent Perforating vein	Venous ablation	Venous thrombosis	Lymph Node Venous Networks	Non-vascular structure	Active or healed ulcer
												
Key for non-colour Worksheet												
Competent	Incompetent	Hypoplastic	Aplastic	Treated thrombosed	Competent Perforating vein	Incompetent Perforating vein	Lymph Node Venous Networks	Non-vascular structure	Venous ulcer			
												



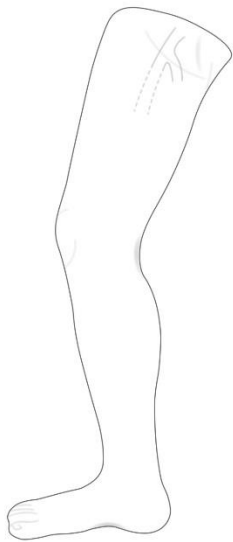
Left groin



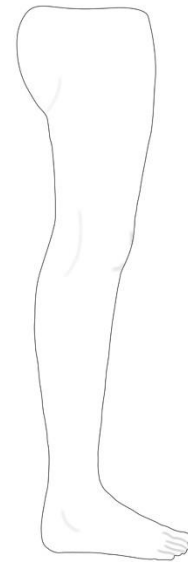
Left posterior knee



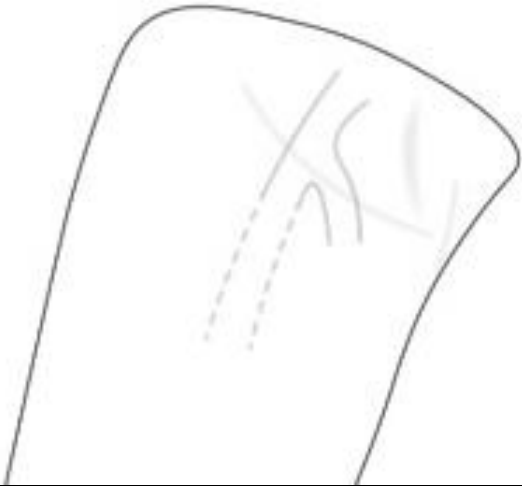Right leg medial



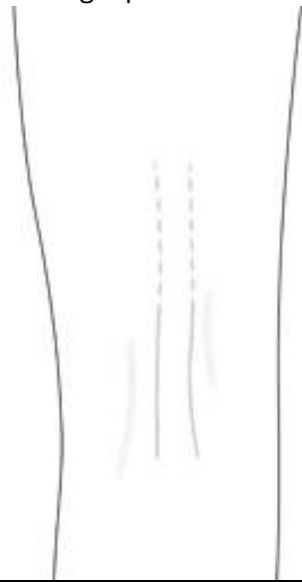Right leg lateral



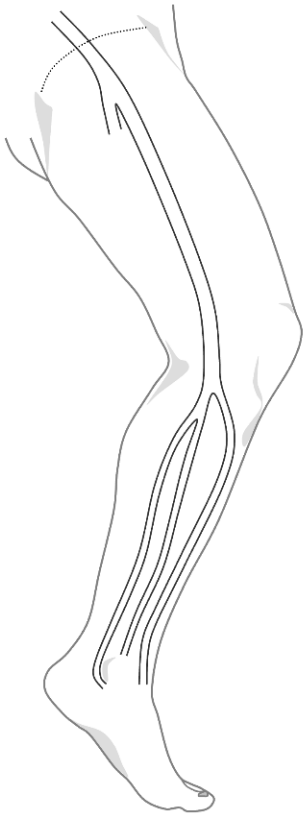
Right groin



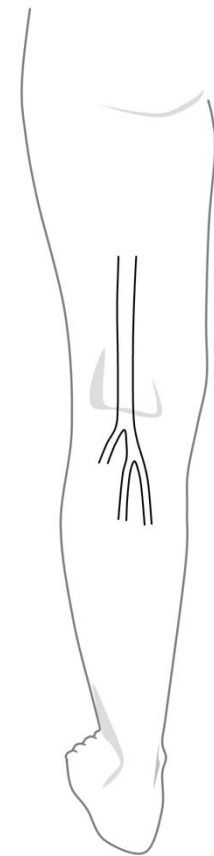
Right posterior knee



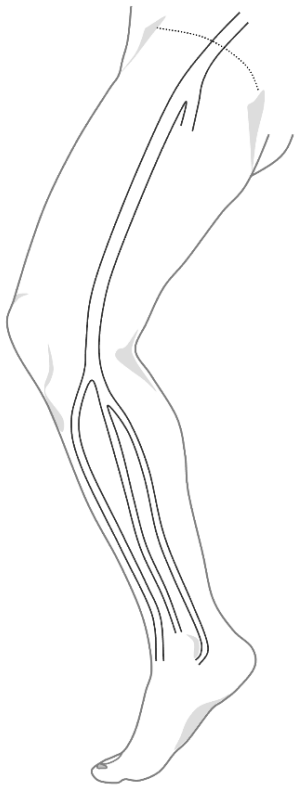
Left leg medial



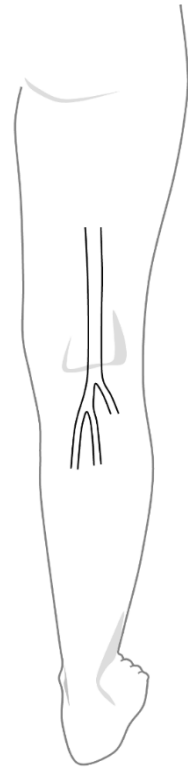
Left leg posterior



Right leg medial



Right leg posterior



DRAFT